

# Study of the association between nailfold capillaroscopic changes and serum level of interleukin-17 in rheumatoid: a clue for emerging vasculitis

H.K. Koryem<sup>a</sup>, M.Y. Tayel<sup>b</sup>, S.S. Eltawab<sup>a</sup>, R.F. Moftah<sup>c</sup>, Omneya E. Elazzay<sup>d</sup>

<sup>a</sup>Departments of Physical Medicine, Rheumatology and Rehabilitation, <sup>b</sup>Internal Medicine, <sup>c</sup>Clinical Pathology, <sup>d</sup>Physical Medicine, Rheumatology and Rehabilitation, New Miami, Alexandria, Egypt

Correspondence to Omneya E. Elazzay, New Miami, Alexandria, Egypt  
Tel: +20 100 196 6446;  
e-mail: manmoni@yahoo.com

Received 16 April 2016

Accepted 22 June 2016

**Egyptian Rheumatology & Rehabilitation**  
2016, 43:190–195

## Objectives

The aim of this work was to study nailfold capillaroscopic (NC) abnormalities and serum interleukin-17 (IL-17) level among rheumatoid arthritis (RA) patients and to find whether IL-17 is causally involved in the changes in the capillary vascular bed, such as autoimmune prevasculitic changes.

## Patients and methods

The study was conducted on a group of RA Egyptian patients ( $n=40$ ) who were diagnosed as having RA based on ACR criteria. Those 40 patients were further divided into two groups. Group 1 included RA patients with clinical signs of skin vasculitis and NC changes ( $n=6$ ). Group 2 included RA patients with no clinical signs of skin vasculitis and no NC changes ( $n=34$ ). All patients were subjected to demographic data collection, clinical examination, disease activity score 28 calculation, laboratory measurement (including erythrocyte sedimentation rate, C-reactive protein, rheumatoid factor, antinuclear antibody, antineutrophil cytoplasmic antibody, anti-cyclic citrullinated peptide, and IL-17) and NC examination. In addition, group 1 ( $n=6$ ) was further subjected to electrophysiological evaluation using peripheral nerve conduction studies to determine the effect of vasculitis on the peripheral nerves.

## Results

IL-17 level and NC changes showed a significant association in RA vasculitis patients.

## Conclusion

Elevated levels of serum IL-17 and characteristic NC changes raise their importance in the detection of preclinical rheumatoid vasculitis.

## Keywords:

interleukin-17, nailfold capillaroscopy, rheumatoid vasculitis

Egypt Rheumatol Rehabil 43:190–195

© 2016 Egyptian Society for Rheumatology and Rehabilitation  
1110-161X

## Introduction

Rheumatoid vasculitis (RV) is the most serious systemic disease manifestation of rheumatoid arthritis (RA), wherein it manifests almost exclusively in RA patients with rheumatoid autoantibodies and often occurs in the context of other extra-articular manifestations. RV is defined as a clinicopathological manifestation of RA characterized by tissue damage or ischemia verified pathologically by vasculitis [1,2].

The prevalence of RV was estimated at less than 1–5%, whereas autopsy studies have reported 15–31% [3,4].

Three histological patterns of vasculitis may be seen:

- (1) A necrotizing leukocytoclastic vasculitis of dermal venules is seen in patients with palpable purpura, hemorrhagic bullae, maculopapular erythema, and erythema elevatum diutinum [5].
- (2) An acute or healing arteritis of dermal subcutaneous vessels similar to that seen in polyarteritis nodosa is

seen in patients with subcutaneous nodules, livedo reticularis, and ulcers [6,7].

- (3) Other histological patterns that can be seen include folliculocentric microabscess formation resembling dermatitis herpetiformis and granulomatous vasculitis composed mainly of lymphocytes and histocytes [8].

The postulated mechanisms of vessel wall destruction with RV include the following: [9]

- (1) Autoantibody targeting of the vessel [10].
- (2) Incidental inflammation due to deposition of immune complexes [11,12].
- (3) Collateral damage due to a local antigen-driven cellular immune response [13].

This is an open access article distributed under the terms of the Creative Commons Attribution-NonCommercial-ShareAlike 3.0 License, which allows others to remix, tweak, and build upon the work noncommercially, as long as the author is credited and the new creations are licensed under the identical terms.

RV may involve virtually any organ of the body, but the most common sites of involvement are the skin and peripheral nerves, as in many series the skin or peripheral nerves are involved in more than 80% of RV patients. Major organ system involvement of the heart, bowel, or kidney is much less common but can lead to significant morbidity and mortality, including myocardial infarction, bowel ischemia, and renal failure; although central nervous system involvement is rare, many case reports describe its occurrence [14,15].

Interleukin-17 (IL-17) or IL-17 A is a member of a group of cytokines called IL-17 family (including IL-17 B, IL-17C, IL-17 D, IL-17 E, and IL-17 F). Among all members, the biological functions and regulations of IL-17 A and IL-17 F are best understood [16,17]. Specialized T cells, called T-helper 17 cells, are the major sources of IL-17 A and IL-17 F in many types of adaptive immunity; however, recently, other contributors to IL-17 A and IL-17-F production, mainly in the innate arm of the immune system, were identified [18].

Although crucial in protecting the host from invasion by many types of pathogens, dysregulated IL-17 production can result in excessive proinflammatory cytokine expression and chronic inflammation, which lead to tissue damage and autoimmunity [19,20].

IL-17 has a role in chronic vascular inflammation of atherosclerosis and possibly hypertensive vascular changes, whereas in acute inflammation IL-17 is elevated and may be causally involved in the autoimmune vasculitides [21–25].

Nailfold capillaroscopy (NC) was used during the beginning of the 20th century, to show in detail the abnormalities that characterize the involvement of microvasculature during Raynaud's phenomenon in systemic sclerosis [26].

NC represents the best method to analyze microvascular abnormalities in autoimmune rheumatic diseases [27].

In addition, capillaroscopic changes have been observed in systemic sclerosis, systemic lupus erythematosus, antiphospholipid syndrome, and Sjogren's syndrome, but still further epidemiological and clinical studies are needed to better standardize the NC patterns [28].

---

## Aim

The aim of this study was to study NC abnormalities and serum IL-17 level among RA patients and to find

whether IL-17 is causally involved in the changes in the capillary vascular bed, such as autoimmune prevasculitic changes.

---

## Patients and methods

The current study was conducted on 40 RA patients who were diagnosed according to the current 2010 ACR-EULAR criteria for diagnosis of RA. All patients gave their formal consent. The protocol was approved the Ethical committee of the Alexandria University.

Exclusion criteria included any disease or medication causing vasospasm, any other rheumatic disease, diabetes mellitus, and having hepatitis B or C viruses.

All patients were subjected to demographic data collection, historical data, clinical examination, calculation of disease activity score 28 (DAS 28), laboratory measurement [including erythrocyte sedimentation rate, C-reactive protein (CRP), rheumatoid factor (RF), anti-cyclic citrullinated peptide (anti-CCP), antinuclear antibody (ANA), antineutrophil cytoplasmic antibody (ANCA) 'both types P and C', and IL-17], and NC, wherein the following capillaroscopic parameters were evaluated using an ophthalmoscope: distribution, presence of dilatation, presence of avascular areas, hemorrhages, and neoangiogenesis.

Thereafter, the 40 patients were further divided into two groups based on the presence or absence of NC changes: RA patients with NC changes (group 1;  $n=6$ ) and RA patients with no NC changes (group 2;  $n=34$ ).

Thereafter, the six patients included in group 1 were further subjected to electrophysiological studies (in upper limbs: the median nerve and the ulnar nerve; and in the lower limb: the sural nerve and the posterior tibial nerve).

---

## Results

The data collected from patients and controls were tabulated and statistically analyzed to study NC abnormalities and serum IL-17 pattern among RA patients with suspected vasculitis by positive NC changes and those with negative capillaroscopy.

The NC changes that were found in group 1 ( $n=6$ ) were tabulated.

RA patients with NC changes (group 1) showed clinical evidence of skin vasculitis, which in our studied patients were as follows: three patients suffered from purpuric rash, two patients suffered from small ulcers on the feet

and big toe, and one patient suffered from livedo reticularis. All patients included in group 2 with no NC changes showed no clinical manifestations of skin vasculitis.

Patients of group 1 (n=6) showed the same electro-physiological findings and were as follows: absent sural nerve and normal conduction of other nerves.

DAS 28 showed a significant difference between RA patients with no NC changes (n=34) and RA patients with NC changes (n=6) (Table 1 and Fig. 1).

Twenty-one patients showed moderate disease activity (DAS 28 >3.2 and ≤5.1) and the remaining 19 patients showed severe disease activity (DAS 28 >5.10). The six RA patients with vasculitic changes were all found to show severe activity (DAS 28 >5.1).

Erythrocyte sedimentation rate and anti-CCP showed no significant difference between RA patients with no NC changes (n=34) and RA patients with NC changes (n=6). In contrast, CRP and RF showed a significant difference between those two groups (P=0.010 and 0.001, respectively) (Table 2 and Figs 2 and 3).

ANA was compared between RA patients with no NC changes (n=34) and RA patients with NC changes (n=6), and it showed no significant difference (Table 3).

ANCA (both types showed the same results) showed a significant difference between RA patients with no NC changes (n=34) and RA patients with NC changes (n=6) (P=0.021) (Table 3 and Fig. 4).

When IL-17 serum level was compared between RA patients with NC changes (n=6) and RA patients with no NC findings (n=34), a significant difference was found (P<0.001) (Tables 4 and 5 and Fig. 5).

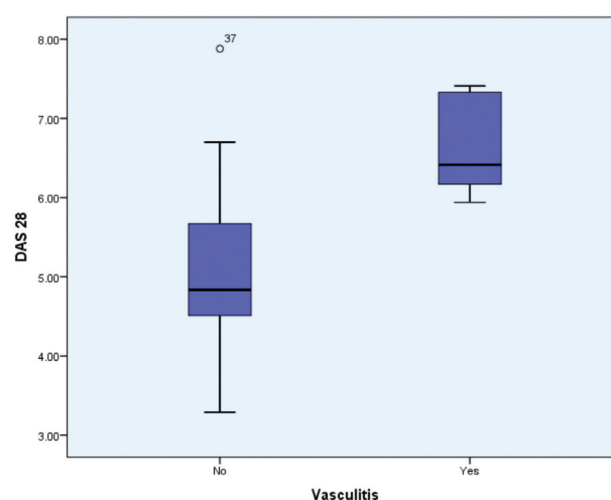
### Discussion

The present study included 40 RA patients, of whom only six patients were diagnosed clinically as having RV. This is in agreement with the results of previously published data by Puechal *et al.* [4], which estimated the prevalence of RV at less than 1–5% in patients and 15–30% in autopsy. Similarly, Loricera *et al.* [29] reported a low incidence of RV.

In addition, the current study estimated that the incidence of NC changes is the same as the incidence of vasculitis in the studied patients, which shows that NC changes occur in parallel with clinical vasculitic changes. Similarly, Souza and Kayser [30] concluded that NC changes were associated with vascular disorders.

In contrast, Hachulla *et al.* [31] concluded the opposite, as the results showed that capillaroscopy when compared between RA patients with and those without vasculitis showed no difference, and this was attributed to the fact that the regular capillaroscopy was not accurate in detecting the vascular changes in the nailbed of RV patients.

Figure 1



Box plot showing disease activity score 28 (DAS 28) range in rheumatoid arthritis patients with and without nailfold capillaroscopic changes.

Table 2 Disease activity score 28 in rheumatoid arthritis with nailfold capillaroscopic changes and rheumatoid arthritis patients with no nailfold capillaroscopic changes

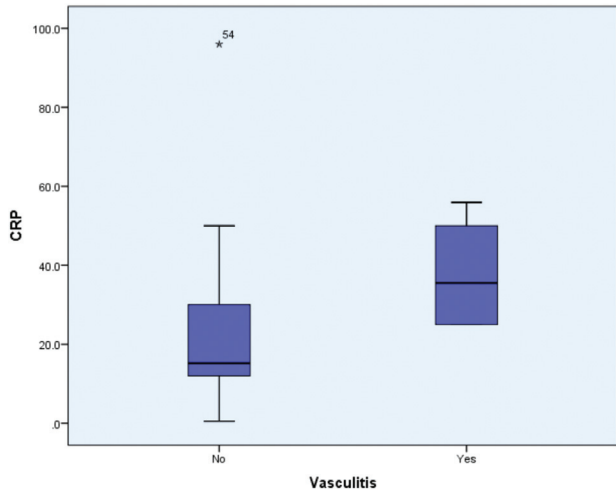
	RA patients with NC changes (group 1) (N=6) (15%)	RA patients without NC changes (group 2) (N=34) (85%)	P
DAS 28			
Median (min.–max.)	6.41 (5.94–7.41)	4.83 (3.29–7.88)	0.001*

DAS, disease activity score; min., minimum; max., maximum; NC, nailfold capillaroscopic; RA, rheumatoid arthritis. \*P<0.05 are significant.

Table 1 Nailfold capillaroscopic changes

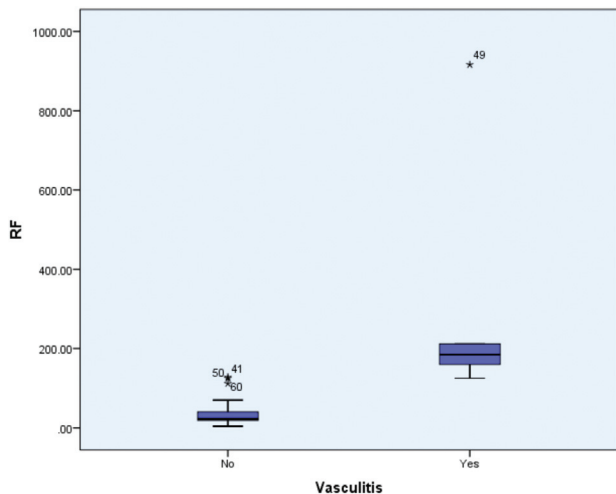
Patient 1	Patient 2	Patient 3	Patient 4	Patient 5	Patient 6
Loops dilated, areas of hemorrhage, and avascular areas	Loops dilated, areas of hemorrhage, and avascular areas	Dilated loops, and areas of hemorrhage.	Dilated loops, hemorrhage, and avascular areas	Dilated loops	Dilated loops

Figure 2



Box plot showing the range of C-reactive protein (CRP) among the two groups, rheumatoid arthritis (RA) patients with nailfold capillaroscopic (NC) changes (group 1), and RA patients with no NC changes (group 2).

Figure 3



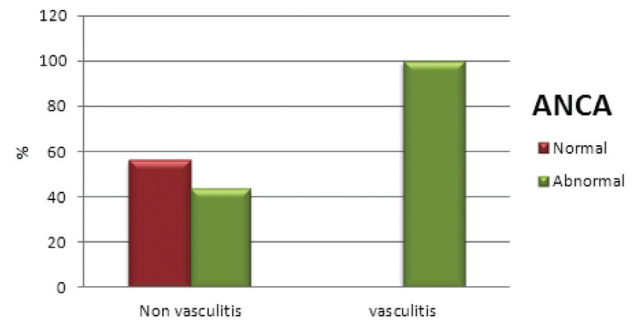
Box plot showing rheumatoid factor (RF) among the two groups, rheumatoid arthritis (RA) patients with nailfold capillaroscopic (NC) changes (group 1), and RA patients with no NC changes (group 2).

Table 3 Comparison of C-reactive protein and rheumatoid factor between rheumatoid arthritis patients with nailfold capillaroscopic changes and rheumatoid arthritis patients with no nailfold capillaroscopic changes

	RA patients with NC changes (N=6) (15%)	RA patients without NC changes (N=34) (85%)	P
CRP (U/ml)			
Median <sup>a</sup> (min.–max.)	35.5 (25–55.9)	15.2 (0.5–96)	0.010*
RF (IU/ml)			
Median <sup>a</sup> (min.–max.)	185 (125–916.4)	22.6 (4–128)	0.001*

CRP, C-reactive protein; min., minimum; max., maximum; NC, nailfold capillaroscopic; RA, rheumatoid arthritis; RF, rheumatoid factor. <sup>a</sup>Mann–Whitney test. \*P≤0.05 are significant.

Figure 4



Bar chart showing the level of antineutrophil cytoplasmic antibody (ANCA) between the two groups, rheumatoid arthritis with and without nailfold capillaroscopic changes.

Table 4 Comparison of antinuclear antibody and antineutrophil cytoplasmic antibody levels between rheumatoid arthritis patients with nailfold capillaroscopic changes and rheumatoid arthritis with no nailfold capillaroscopic changes

	RA patients with NC changes (group 1) (N=6) (15%)	RA patients without NC changes (group 2) (N=34) (85%)	P
ANA [n (%)]			
Normal titer	1 (16.7)	6 (17.6)	FE=1
High titer	5 (83.3)	28 (82.4)	
ANCA [n (%)]			
Negative	0 (0)	19 (55.9)	FE=0.021*
Positive	6 (100)	15 (44.1)	

ANA, antinuclear antibody; ANCA, antineutrophil cytoplasmic antibody; FE, Fischer exact test; NC, nailfold capillaroscopic; RA, rheumatoid arthritis. \*P≤0.05 are significant.

Table 5 Comparison of interleukin-17 diagnostic significance between rheumatoid arthritis patients with nailfold capillaroscopic changes and rheumatoid arthritis patients with no nailfold capillaroscopic changes

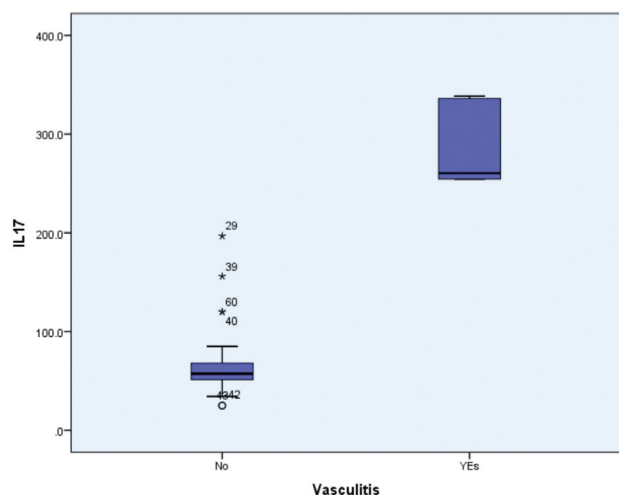
	RA patients with NC changes (group 1) (N=6) (15%)	RA patients without NC changes (group 2) (N=34) (85%)	P
IL-17 (pg/ml)			
Median <sup>a</sup> (min.–max.)	260.4 (254.4–338.4)	57.3 (25–196.8)	<0.001*

IL-17, interleukin-17; min., minimum; max., maximum; NC, nailfold capillaroscopic; RA, rheumatoid arthritis. <sup>a</sup>Mann–Whitney test. \*P≤0.05 are significant

This study showed a significant difference in DAS 28 between RA patients and RV patients, and concluded that patients with higher DAS 28 score were associated with vasculitic changes. This means that vasculitis in RA occurs in the disease with high activity as scored with DAS 28 in the studied patients.

Similarly, Shanmugan *et al.* [32] calculated DAS 28 in RA patients before and after the appearance of

Figure 5



Box plot representing interleukin-17 (IL-17) level in rheumatoid arthritis patients with and without vasculitis.

vasculitic ulcer, and it was concluded that there were significant increases in DAS 28 score, which implied a significant difference. In contrast, Mederos *et al.* [33] concluded that there were discrepancies in data from DAS 28 and recommended to define better score with better cutoff.

In the current study, anti-CCP had no significant difference between RA and RV patients. This implies that anti-CCP is rather a diagnostic than a follow-up tool and its level does not reflect associated vascular abnormalities. In agreement, Wiik *et al.* [34] concluded that, although anti-CCP is considered an important marker of progressive erosive disease and extra-articular manifestations such as vasculitis, this was hampered by doubt about a positive versus negative reaction in several assays. Korkmaz *et al.* [35] also concluded that anti-CCP does not seem to have much linkage with extra-articular manifestations of RA.

In contrast, Turesson *et al.* [36] concluded that anti-CCP levels tend to be higher in patients with RA with vasculitis than in those without vasculitis.

We showed reports that RF showed a significant difference between RA and RV patients, and it was higher in RV patients ( $P=0.001$ ). This means that RF is highly linked and associated with vascular activity.

Similarly, Khasnis and Langford [37] and Turesson and Matterson [38] concluded that RF level is higher in vasculitis.

In contrast, Tourin *et al.* [39] proved that RA-associated vasculitis is associated with low titer-positive RF.

The current study illustrated that there was a significant difference in CRP between RA and RV patients, and CRP was higher in the RV group ( $P=0.010$ ). This reflects the concluded association between CRP and vasculitic changes. Similarly, Suresh [40] concluded the association of high levels of CRP with RV. Moreover, Kobak *et al.* [41] showed that there was a significant difference in CRP between RA and RV patients.

This is contradictory to that reported by Senolt *et al.* [42], who showed that CRP can be normal in RA with or without extra-articular manifestations.

The current study concluded that there was no significant difference in ANA between RA and RV patients. This means that ANA is not associated with vasculitic changes in our studied patients.

In agreement, De Souza *et al.* [43] proved that ANA can be negative, with no significant difference in RV. In contrast, Voskuyl *et al.* [44] proved that ANA is positive and had significant difference in RV patients.

The current study concluded that ANCA showed a significant difference between RV patients and RA patients ( $P=0.021$ ). This means that ANCA is associated with vasculitic changes occurring on top of RA in our studied patients.

Similarly, Voskuyl *et al.* [44] concluded that there is a significant difference in ANCA between RA and RV patients.

In contrast, Puechal [45] and Suresh [40] excluded the possibility of the presence of a significant difference between RA and RV patients.

The current study concluded that there was a significant difference in IL-17 between RV and RA patients, wherein it was more significant in RV patients ( $P\leq 0.001$ ). This means that IL-17 is highly associated with the development of vasculitic changes.

In agreement, Hoshino *et al.* [46] concluded that there is an association between IL-17 and vasculitis. There were no studies to prove otherwise.

Finally, IL-17 and NC changes were proved in our study to have a role in RV.

Drawbacks in the current study include the following: (a) the sample size of RV patients was small, and (b) RV patients were diagnosed on the basis of the clinical skin evaluation and laboratory measurements, and no biopsy was done.

## Conclusion

Elevated levels of serum IL-17 and characteristic NC changes raise their importance in the detection of preclinical RV.

## Financial support and sponsorship

Nil.

## Conflicts of interest

There are no conflicts of interest.

## References

- Mayasoedova E, Crowson CS, Turesson C. Incidence of extraarticular rheumatoid arthritis in Olmsted county Minnesota in 1995-2007 versus 1985-1994: a population based study. *J Rheumatol* 2011; 28:983-989.
- Barlds CM, Bridges J. Rheumatoid vasculitis: vanishing menace or target of a new treatment?. *Curr Rheumatol Rep* 2010; 12:414-419.
- Assmann G, Pfreundschuh M, Voswinkel J. Rituximab in patients with rheumatoid arthritis and vasculitis – associated cutaneous ulcers. *Clin Exp Rheumatol* 2010; 28:81-83.
- Puechal X, Gottenberg JE, Berthelot JM. Rituximab therapy for systemic vasculitis associated with rheumatoid arthritis: results from the Autoimmunity and Rituximab Registry. *Arthritis Care Res (Hoboken)* 2012; 64:331-339.
- Chen K, Carlson J. Clinical approach to cutaneous vasculitis. *Am J Clin Dermatol* 2008; 9:71-92.
- Carlson J, Chen K. Cutaneous vasculitis update: small vessel neutrophilic vasculitis syndrome. *Am J Dermatol Pathol* 2006; 28:486-506.
- Chen K. The misdiagnosis of superficial thrombophlebitis as cutaneous polyarteritis nodosa: features of intimal elastic lamina and the compact concentric muscular layer as diagnostic pitfalls. *Am J Dermatol Pathol* 2010; 32:688-693.
- Margo C, Crowson A. The spectrum of cutaneous lesions in rheumatoid arthritis: a clinical and pathological study of 43 patients. *J Cutan Pathol* 2003; 30:1-10.
- Chang SH, Dong C. Signaling of interleukin-17 family cytokines in immunity and inflammation. *Cell Signal* 2011; 23:1069-1075.
- Yao Z, Fanslow WC, Seldin MF. Herpesvirus Saimiri encodes a new cytokine, IL-17, which binds to a novel cytokine receptor. *Immunity* 1995; 3:811-821.
- Albanesi C, Scarponi C, Cavani A, Federici M, Nasorri F, Girolomoni G. Interleukin-17 is produced by both Th1 and Th2 lymphocytes and modulates interferon-gamma-and interleukin-4-induced activation of human keratinocytes. *Invest Dermatol J* 2000; 115:81-87.
- Lenarczyk A, Helsloot J, Farmer K, Peters L, Sturgess A, Kirkham B. Antigen-induced IL-17 response in the peripheral blood mononuclear cells (PBMC) of healthy controls. *Clin Exp Immunol* 2000; 122:41-48.
- Milner JD, Brenchley JM, Laurence A. Impaired Th17 cell differentiation in subjects with autosomal dominant hyper-IgE syndrome. *Nature* 2008; 452:773-776.
- Turesson C, Jacobsson LT. Epidemiology of extra-articular manifestations in rheumatoid arthritis. *Scand J Rheumatol* 2004; 33:65-72.
- Genta MS, Genta RM, Gabay C. Systemic rheumatoid vasculitis: a review. *Semin Arthritis Rheum* 2006; 36:88-98.
- Hymowitz SG, Filvaroff EH, Yin JP, Lee J, Cai L, Risser P, *et al.* IL-17 adopt a cysteine knot fold: structure and activity of a novel cytokine, IL-17 F and implication for receptor binding. *EMBO J* 2001; 20:5332-5341.
- Wang X, Zhang Y, Yang XO. Transcription of IL17 and IL17 F is controlled by conserved noncoding sequence 2. *Immunity* 2011; 34:149-162.
- Wakura Y, Ishigame H, Saijo S, Nakae S. Functional specialization of IL-17 family members. *Immunity* 2011; 34:149-162.
- Inchaud M, Fossiez F, Taupin JL, Miossec P. Enhancing effect of IL-17 on IL-1 induced IL-6 and leukemia inhibitory factor production by rheumatoid arthritis synovial cells and its regulation by Th2 cytokines. *J Immunol* 1998; 161:409-414.
- Nakae S, Nambu A, Sudo K, Iwakura Y. Suppression of immune induction of collagen induced arthritis in IL-17 deficient mice. *J Immunol* 2003; 171:6173-6177.
- Garrett-Sinah LA, John S, Gaffen SL. IL-17 and Th17 lineage in systemic lupus erythematosus. *Curr Opin Rheumatol* 2008; 20:519-525.
- Satio H, Tsurikiswa N, Tsuburai T, Oshikata C, Akiyama K. Cytokine production profile of CD4 T cells from patients with active Churg-Strauss syndrome tends toward Th17. *Int Arch Allergy Immunol* 2009; 149:61-65.
- Crispin JC. Expanded double negative T cells in patients with systemic lupus erythematosus produce IL-17 and infiltrate the kidneys. *J Immunol* 2008; 181:8761-8766.
- Zhang Z, Kytitaris VC, Tsoko GC. The role of IL-23/IL-17 axis in lupus nephritis. *J Immunol* 2009; 183:3160-3169.
- Paust HJ, Turner JE, Steinmetz OM, Peters A, Heymann F, Hölscher C, *et al.* The IL-23/Th17 axis contributes to renal injury in experimental glomerulonephritis. *J Am Soc Nephrol* 2009; 20:969-979.
- Brown GE, O'Leary PA. Skin capillaries in scleroderma. *Arch Intern Med* 1925; 36:73-88.
- Scantelbury D, Prasad A, Rabinstein A, Best P. Prevalence of migraine and Raynaud's phenomenon in women with apical ballooning syndrome (Takotsubo or stress cardiomyopathy). *Am J Cardiol* 2013; 111:1284-1288.
- Cutolo M, Suilli A, Secchi M, Pizzoroni C. The contribution of capillaroscopy to the differential diagnosis of connective tissue diseases. *Best Pract Res Clin Rheumatol* 2007; 21:1093-1108.
- Loricera J, Blanco R, Hernandez JL, Carril JM, Martínez-Rodríguez I, Canga A, *et al.* Non-infectious aortitis: a report of 32 cases from a single tertiary centre in a 4-year period and literature review. *Clin Exp Rheumatol* 2015; 33:S19-S31.
- Souza EJ, Kayser C. Nailfold capillaroscopy: relevance to the practice of rheumatology. *Rev Bras Rheumatol* 2015; 55:264-271.
- Hachulla E, Perez M, Flipo RM, Hourengel E, Cardon T, Catteau MH, *et al.* Increased capillary permeability in systemic rheumatoid vasculitis: detection by dynamic fluorescence nailfold videomicroscopy. *J Rheumatol* 1994; 21:1197-1202.
- Shanmugan VK, DeMaria DM, Attinger CE. Lower extremity ulcers in rheumatoid arthritis: features and response to immunosuppression. *Clin Rheumatol* 2011; 30:849-853.
- Mederos M, de Oliveira B, de Cerqueira J, Quixada R, de Oliveira I. Correlation of rheumatoid arthritis activity indexes (disease activity score 28 measures with ESR and CRP, simplified disease activity index and clinical disease activity index) and agreement of disease activity states with various cut-off points in a Northeastern Brazilian population. *Rev Bras Rheumatol* 2015; 55:395-468.
- Wiik A, Venrooij W, Pruijn G. All you wanted to know about anti-CCP but were afraid to ask. *Autoimmun Rev* 2010; 10:90-93.
- Korkmaz C, Us T, Kasifoglu T, Akgun Y. Anti-cyclic citrullinated peptide antibodies in patients with long-standing rheumatoid arthritis and their relationship with extra-articular manifestations. *Clin Biochem* 2006; 39:961-965.
- Turesson C, Jacobsson LTH, Sturfelt G. Rheumatoid factor and antibodies to cyclic citrullinated peptides are associated with severe extra-articular manifestations in rheumatoid arthritis. *Ann Rheum Dis* 2007; 66:70-75.
- Khasnis A, Langford CA. Update on vasculitis. *J Allergy Clin Immunol* 2009; 123:1226-1236.
- Turesson C, Matterson EL. Extraarticular features of rheumatoid arthritis. In: Hochberg MC, Silman AJ, Smolen JS, editors. *Rheumatology*. 4th ed. Philadelphia, PA: Mosby; 2008. 773-783.
- Tourin O, Carazo S, Smith D, Fischer A. Pulmonary vasculitis as the first manifestation of rheumatoid arthritis. *Resp Med Case Rep* 2013; 8:40-42.
- Suresh E. Diagnostic approach to patients with suspected vasculitis. *Postgrad Med* 2006; 82:483-488.
- Kobak S, Yilmaz H, Yalcin M, Karaalslan A. Digital vasculitis in a patient with rheumatoid arthritis responded well to adalimumab. *Case Rep Rheumatol* 2014; 2014:416825.
- Senolt L, Grassi W, Szodoray P. Laboratory biomarkers or imaging in the diagnostics of rheumatoid arthritis? *BMC Med* 2014; 18:12-49.
- De Souza A, Rosa D, Buosi A, Oliveira A, Natour J. Testicular vasculitis – a rare manifestation of rheumatoid arthritis. *Rev Bras Rheumatol* 2013; 54: 365-367.
- Voskuyl A, Hazes J, Zwinderman A, Paleolog E, De Meer F, Daha M, Breedveld F. Diagnostic strategy for the assessment of rheumatoid vasculitis. *Ann Rheum Dis* 2003; 62:407-413.
- Puechal X. Rheumatoid arthritis vasculitis. *Presse Med* 2013; 42:527-530.
- Hoshino A, Nagoa T, Suzuki K. MPO-ANCA induces IL17 production by activated neutrophils in vitro via its FC region and complement dependent manner. *J Autoimmun* 2008; 31:79-89.