

# Magnetic resonance diagnosis of adhesive capsulitis of the shoulder

Reddy Ravikanth, Kanagasabai Kamalasekar

Department of Radiology, Holy Family Hospital,  
Thodupuzha, Kerala, India

Egypt Rheumatol Rehabil 46:208–209  
© 2019 Egyptian Society for Rheumatology and Rehabilitation  
1110-161X

Correspondence to Reddy Ravikanth, MD,  
DNB, Department of Radiology, Holy Family  
Hospital, Thodupuzha 685605, Kerala, India.  
Tel: +91-7902873693; fax: 04862-221061;  
e-mail: ravikanthreddy06@gmail.com

**Received** 27 September 2018

**Accepted** 6 January 2019

**Egyptian Rheumatology & Rehabilitation**  
2019, 46:208–209

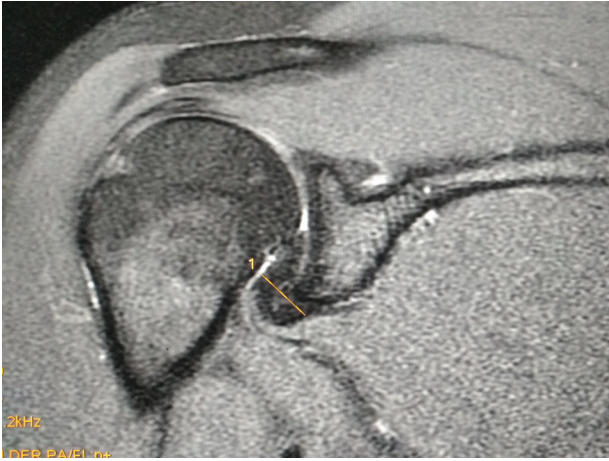A 38-year-old male presented with shoulder pain since 2 months with no history of trauma. MRI showed poor definition and thickening of coracohumeral ligament measuring 5.3 mm with abnormal intermediate amorphous signal (with hypointense foci on all sequences) surrounding the ligament with ill definition of superior glenohumeral ligament and rotator interval, thickening of the inferior glenohumeral ligament in the axillary pouch measuring 13.8 mm, and mild free fluid in the shoulder joint – likely suggesting adhesive capsulitis (Figs 1 and 2). There was associated thickening and diffuse T2 hyperintensity of the long head biceps tendon anchor suggesting tendinitis. Adhesive capsulitis is most common in the age group 45–60 years, a population for whom magnetic resonance arthrography is rarely ordered [1]. It is characterized by a painful restriction of shoulder motion that results in fibrosis and contracture of the glenohumeral joint capsule. Adhesive capsulitis is a clinical condition of progressive pain and decreased range of motion of the glenohumeral joint. Primary adhesive capsulitis is an idiopathic condition characterized by the insidious onset of symptoms, most commonly seen in women older than 40 years, generally without an antecedent inciting event or medical/surgical condition, although diabetes mellitus and hypothyroidism are risk factors for primary type. Secondary causes of adhesive capsulitis include history of severe trauma and prior surgery [2]. The diagnosis and staging of adhesive capsulitis are usually made based on clinical symptoms and physical examination alone. However, clinical diagnosis of adhesive capsulitis is often challenging because many conditions in and around the glenohumeral joint manifest with overlapping clinical features, and no diagnostic criteria for adhesive capsulitis has been established yet. MRI is not widely accepted as a reliable modality for

confirming the diagnosis of adhesive capsulitis. Noncontrast MRI can be used to accurately diagnose adhesive capsulitis in conjunction with appropriate clinical criteria. Adhesive capsulitis can be accurately diagnosed on noncontrast MRI shoulder examinations with appropriate clinical criteria without direct magnetic resonance arthrography. Typical MR findings include synovial hypertrophy and debris within the rotator interval seen as replacement of the normal rotator interval fat by granulation tissue or fibrous tissue, thickening of the rotator interval capsule, thickening of the ligaments of the rotator interval, superior glenohumeral ligament (SGHL) and coracohumeral ligament (CHL), thickening of the joint capsule with contracted and non-distensible axillary recess. The thickness of the capsule of the axillary recess is best demonstrated on coronal images at the mid glenoid level. Thickened inferior glenohumeral ligament greater than 4 mm is often seen in the axillary pouch [3]. Magnetic resonance arthrography is the imaging test of choice to assess for adhesive capsulitis. It shows characteristic findings, such as limited shoulder joint capacity and a small or nonexistent dependent axillary fold. However, arthrography is invasive and cannot explore changes in the synovial and capsular membranes. Intravenous gadolinium enhancement increases the specificity of the diagnosis by demonstrating enhancement of the rotator interval capsule and enhancement of the capsuloligamentous structures in the axillary recess. In contrast, MRI is a noninvasive modality and can identify changes in the synovium and the joint capsule

---

This is an open access journal, and articles are distributed under the terms of the Creative Commons Attribution-NonCommercial-ShareAlike 4.0 License, which allows others to remix, tweak, and build upon the work non-commercially, as long as appropriate credit is given and the new creations are licensed under the identical terms.

Figure 1



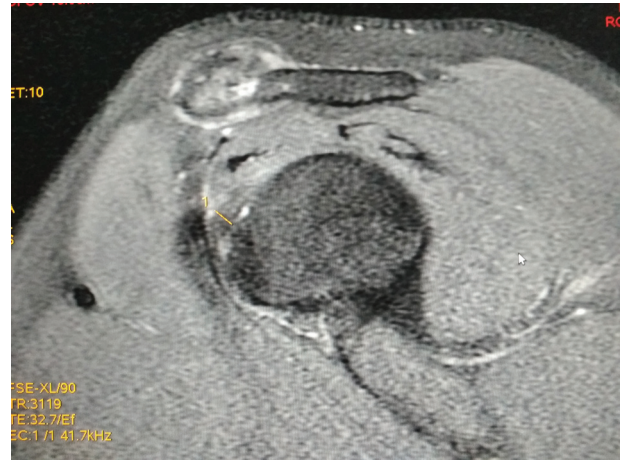
Coronal proton density fat-saturated image demonstrating thickening of the inferior glenohumeral ligament in the axillary recess measuring 13.8 mm.

and can exclude other causes of shoulder pain that mimic adhesive capsulitis such as rotator cuff tear, tendinitis, osteoarthritis, subacromial impingement, and occult fractures. Adhesive capsulitis has been described as self-limiting, but complete resolution may take up to 2 years. Treatment options for adhesive capsulitis have included physiotherapy, corticosteroid injections, closed manipulations, and capsular release.

#### Financial support and sponsorship

Nil.

Figure 2



Sagittal oblique proton density fat-saturated image demonstrating thickening of the coracohumeral ligament measuring 5.3 mm.

#### Conflicts of interest

There are no conflicts of interest.

#### References

- 1 Neviasser JS. Adhesive capsulitis of the shoulder. A study of the pathological findings in periarthritis of the shoulder. *J Bone Joint Surg* 1945; 27:211–222.
- 2 Hannafin JA, Chiaia TA. Adhesive capsulitis: a treatment approach. *Clin Orthop* 2000; 372:95–109.
- 3 Mengiardi B, Pfirrmann CW, Gerber C, Hodler J, Zanetti M. Frozen shoulder: MR arthrographic findings. *Radiology* 2004; 233: 486–492.