

Efficacy of combined paravertebral ozone (O₂O₃) therapy with physiotherapy in patients with chronic mechanical low back pain

Samah Alyan, Rabab Zaghlol, Shima A. Mustafa

Department of Rheumatology and Rehabilitation, Zagazig University, Zagazig, Egypt

Correspondence to Shima A. Mustafa, MD, Lecturer, Department of Rheumatology and Rehabilitation, Zagazig University, Zagazig, Postal 455, Egypt; Tel: 01222694106; e-mail: abuyehia@gmail.com

Received 12 August 2017

Accepted 8 November 2017

Egyptian Rheumatology & Rehabilitation
2018, 45:106–111

Background

Many studies have been done on paravertebral–intramuscular ozone therapy in the management of chronic mechanical low back pain and found that it is effective in pain and function improvement, but none of the studies were done to assess the benefit of addition of paravertebral–intramuscular ozone therapy to the traditional physical therapy in the management of chronic low back pain.

Patients and methods

The study included 160 patients who were diagnosed with chronic mechanical low back pain, and they were divided into two groups: group I included 80 patients treated with paravertebral oxygen–ozone (O₂O₃), infrared lamp therapy, and exercises, and group II included 80 patients treated with infrared lamp therapy and exercises. They were assessed by pain intensity measures such as visual analog scale (VAS) and verbal rating scale (VRS) and functional status measures such as the disability questionnaire – Roland Morris Disability Questionnaire (RMQ) – and the Revised Oswestry Disability Index (ODI). Patients were assessed before treatment, at the end of the treatment (after 4 weeks), and at a follow-up of 24 weeks.

Results

Improvement was achieved in all patients of both groups at 1 month, with statistically highly significant differences between the patients of group I regarding VAS, VRS, RMQ, and ODI scales ($P < 0.001$). We found highly significant differences between the patients of group II regarding RMQ and ODI scales ($P < 0.001$) and statistically significant difference between patients of the same group as regarding VAS and VRS ($P < 0.05$) at 6 months. Group I showed continuous improvement in all variables with highly statistically significant difference ($P < 0.001$) when comparing these with the pretreatment variables at all time points, whereas improvement did not continue with group II at the end of the 24 weeks, as no statistically significant differences were found regarding all measures of outcome scales ($P > 0.05$).

Conclusion

O₂O₃ paravertebral injections combined with physical therapy in patients with chronic mechanical low back pain can offer significantly longer improvement in pain management and functional status in these patients.

Keywords:

low back pain, ozone, physical therapy

Egypt Rheumatol Rehabil 45:106–111

© 2018 Egyptian Society for Rheumatology and Rehabilitation
1110-161X

Introduction

Chronic low back pain (CLBP) is an important healthcare and socioeconomic problem and is associated with high medical expenses, disability, and inability to work. It often shows only minor improvement when treated with conventional therapies in some patients [1].

Conventional pharmacological therapy to reduce pain, inflammation, and functional disability usually relies on the extensive use of pharmacological drugs with frequent association with adverse effects. Thus, new therapeutic options endowed with comparable efficacy and better safety are warranted [2].

Different physical therapy procedures have been recommended for CLBP treatment such as superficial heating, deep heating, exercise therapy, electrotherapy, massage, and spinal manipulation. Finding an effective treatment is a challenge for a medical team [3]. However, because the number of randomized controlled studies investigating the effect of these therapies is limited, there is no consensus on which modalities are more effective in the management of CLBP [4].

This is an open access journal, and articles are distributed under the terms of the Creative Commons Attribution-NonCommercial-ShareAlike 4.0 License, which allows others to remix, tweak, and build upon the work non-commercially, as long as appropriate credit is given and the new creations are licensed under the identical terms.

Many studies have evaluated the effect of superficial heating (infrared lamps and heat wrapping) for treatment of CLBP, and they found that it is effective in relieving pain and improving function but only for short term, with effects lasting only for few days after stoppage of treatment [5,6].

Recently, oxygen or ozone (O_2O_3) therapy has been used successfully in the treatment of low back pain (LBP), reducing pain after the failure of other conservative treatments. Intradiscal and/or intraforaminal administration was initially used, whereas in routine clinical practice, para vertebral–intramuscular infiltration is now the technique mainly used, as it is much less invasive [7].

Several mechanisms of action have been proposed to explain the efficacy of ozone therapy including analgesic, anti-inflammatory, and oxidant action on proteoglycans (e.g. in the nucleus pulposus) [8].

Moreover, the O_2O_3 mixture has been claimed to normalize the level of cytokines and prostaglandins, increase levels of superoxide dismutase, and improve the perineural and perianglionic micro circulation, thereby combating the hypoxia linked to both arterial compression and above all to venous stasis. The mixture also seems to have a reflex therapy effect, being able to break the chain of chronic pain by stimulating anti-nociceptive antalgic mechanisms [9].

Many studies have been conducted on paravertebral–intramuscular ozone therapy in management of CLBP, and they have found that it is effective in pain and function improvement [8], but no studies were done to assess the benefit of addition of paravertebral–intramuscular ozone therapy to the traditional physical therapy in management of CLBP and its long-term effects.

Therefore, the aim of this study was to assess the effect of combined paravertebral O_2O_3 therapy with physiotherapy in chronic mechanical LBP rehabilitation in comparison with physical therapy alone.

Patients and methods

Study design

This study is a prospective nonrandomized clinical trial that was carried out on patients with chronic mechanical LBP.

They were recruited from the outpatient clinic of Rheumatology and Rehabilitation Department in Zagazig University Hospitals.

The study was approved by the Ethics Committee of the University, and informed consent was taken from the patients after providing adequate information about the study (the characteristics of the study, benefits, and possible adverse effects).

Patients

This study was carried out in the period from March 2015 to March 2016.

The study included 160 adult patients of both sexes with a diagnosis of chronic mechanical LBP.

Inclusion criteria

The following inclusion criteria were applied.

- (1) Chronic mechanical LBP of more than 3 months.
- (2) Pain owing to disc protrusion or spondylosis.
- (3) Pain refractory to medical treatment (full dose of NSAIDs with muscle relaxant) for 2 or more weeks.
- (4) Recent MRI within the past 6 months.
- (5) Patients 18 years and older.

Exclusion criteria

We excluded the patients with the following:

- (1) Disc extrusion or sequestration.
- (2) Motor weakness or sensory loss.
- (3) Cauda equina.
- (4) Spondylolisthesis or spondylolysis.
- (5) Severe spinal canal stenosis.
- (6) Obvious scoliosis.
- (7) BMI more than 35.
- (8) No physical therapy received within the past 4 weeks.
- (9) Contraindications to ozone like favism and pregnancy.
- (10) Fracture.
- (11) Previous lumbar operation within the past 3 months.
- (12) Severe systemic illness.
- (13) Rheumatologic, oncogenic, or neurogenic disorder or systemic infection.

Group I

It included 80 patients treated using paravertebral O_2O_3 mixture with infrared therapy and exercises (38 males and 42 females).

Group II

It included 80 patients treated using physical therapy alone (infrared lamp therapy and exercises) (40 males and 40 females).

Methods

(1) Clinical evaluation, routine physical examination, and neurological investigation data were collected for all patients in a clinical sheet.

(2) Standard radiography (anterior–posterior and lateral radiographs) was done for the lumbosacral spine.

(a) MRI was requested if there is no evidence of recent MRI within the past 6 months.

(3) Outcome measures:

The used measures were pain intensity measures, quantified using (i) a 10-cm visual analog scale (VAS), where the patient is asked to mark on a millimetric scale from 0 (absence of pain) to 10 (the worst pain imaginable) the degree of intensity of LBP and (ii) verbal rating scale (VRS) graded on a six-point scale (no pain, very slight, mild, moderate, severe, and intolerable pain).

The other used measures were functional status measures: (i) a disability questionnaire – Roland Morris Disability Questionnaire (RMQ) [10], which consists of 24 questions answered with yes or no response for each, range 0–24 points, and the Revised Oswestry Disability Index (ODI) [11], which consists of 10 items assessing the level of pain and interference with several physical daily activities, with six response options per item with an overall score of 0–50.

(4) Patients were assessed before first treatment, at the end of the treatment (after 4 weeks), and at a follow-up of 24 weeks after the last treatment.

The patients were classified into two different groups of treatment.

Group I

It included 80 patients who were subjected to O₂O₃ mixture (20 ml), with an O₃ concentration of 20 g/ml, obtained by means of a HAB heRRMANN Apparate bau GmbH generator (Germany). The intramuscular injection was administered in the paraspinal lumbar muscles, bilaterally (10 ml for each side), under sterile conditions, using a 22-G needle. The sites most frequently treated were those corresponding to L4–L5 (65%) and L5–S1 (25%). The infiltration point was kept constant at 2 cm from the spinous process of the diseased space. Multilevel treatments were usually performed (one level above and below the affected one). An injection time of 15 s was used, as a

longer injection time was deemed unsuitable because of the instability of medical O₃, which starts decaying (2 g/ml) after about 20 s. No premedication or anesthesia was given, and four paravertebral infiltrations were given once weekly on an outpatient basis.

Group II

The routine physical therapy group received infrared therapy, which was provided by two small, portable units. These units met the safety standards for Food and Drug Administration portability and are registered with the Food and Drug Administration as a therapeutic device. The unit converted electricity to infrared energy at 800–1200 nm wavelength. The patients also receive exercise program that included mobilization, stretching, and strengthening exercises for back and abdominal muscles. The physical therapy program was applied three times a week for 4 weeks.

Statistical analysis

Data were entered, checked, and analyzed by SPSS 10 software package (Chicago, USA). Quantitative data are summarized by mean and SD for parametric data. Nonparametric data are presented by median.

P value less than 0.05 was considered statistically significant, and *P* value less than 0.001 was considered highly significant.

Differences between the groups regarding demographics were analyzed using *t*-test, paired *t*-test, and Fisher's exact test.

Results

A total of 160 CLBP patients were included in the study, with 82 (51.25%) females and 78 (48.75%) males. No differences were found between the two groups regarding the evaluated variables at the baseline, including age, sex, and duration of pain (*P*>0.05), as shown in Table 1.

After the completion of the first month of treatment, we found that the detected parameters showed a real improvement in all patients of both groups, with statistically highly significant differences between the patients of group I regarding all the evaluated variables (VAS, VRS, RMQ, and ODI scales) (*P*<0.001). Moreover, we found highly significant differences between the patients of group II regarding the evaluated variables RMQ and ODI scales (*P*<0.001 and <0.001, respectively) and statistically significant difference between patients of the same group as regarding VAS and VRS scales (*P*<0.05 and <0.05, respectively) (Table 2).

However, this improvement did not continue with group II at the end of the 24 weeks after treatment stoppage, as no statistically significant differences were found regarding all measures of outcome (VAS, VRS, RMQ, and ODI scales) ($P>0.05$) when comparing these with pretreatment measures; on the contrary, group I showed continuous improvement in all variables (VAS, VRS, RMQ, and ODI scales) with a highly statistically significant difference ($P<0.001$) when comparing these with the pretreatment variables. So, the combined ozone and physical therapy group showed significantly better outcomes at the end of the follow-up period than the ones observed in the physiotherapy alone group.

Figures 1–4 showed that both treatment groups had a significant reduction in pain intensity and disability in daily life activity at the end of treatment (first month), but this effect was not maintained up to the end of the follow-up period (24 weeks) in the group treated with physical therapy alone, whereas it was maintained in the combination therapy of ozone and physical therapy group.

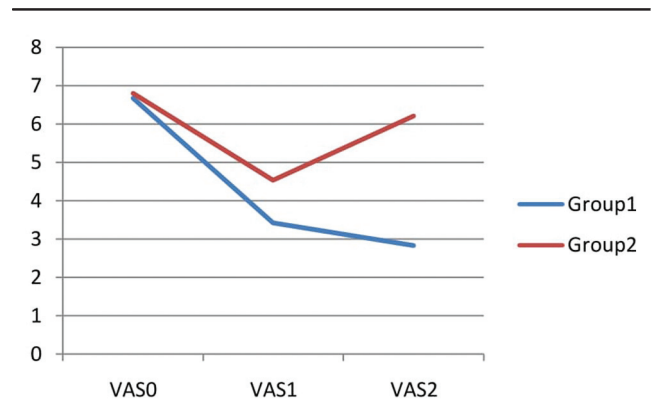
Discussion

The present study was conducted to evaluate the effectiveness of paravertebral O_2O_3 infiltration in the paraspinal lumbar muscles combined with physical therapy in patients with CLBP, comparing it with

the routine physical therapy alone. In our study, the patients were followed up for 6 months to ascertain whether improvements lasted over time in both groups.

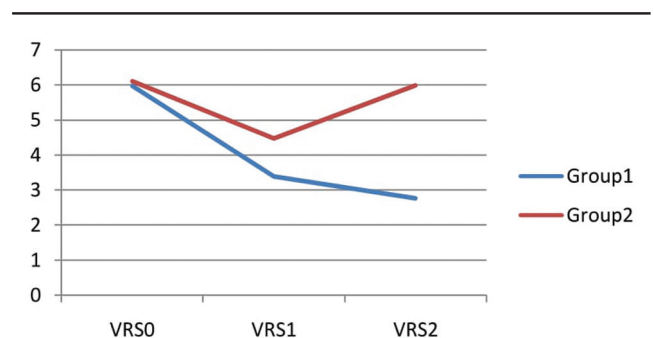
The two groups showed no statistically difference at baseline regarding age, sex, and pain duration. All patients received treatment for 4 weeks and were evaluated at the end of these 4 weeks, and the final evaluation was performed after 24 weeks.

Figure 1



The mean value of visual analog scale (VAS) of the two groups.

Figure 2



The mean value of verbal rating scale (VRS) of the two groups.

Table 1 Baseline characteristics of both groups

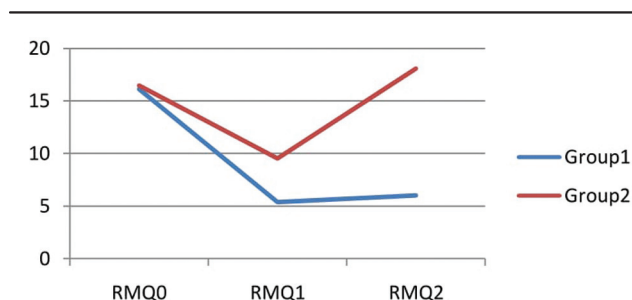
Baseline characteristics	Group I (n=80)	Group II (n=80)	P value
Age (years)	40.03±8.84	38.81±8.75	0.787
Sex (male/female)	38/42	40/40	0.658
Pain duration (months)	7.62±2.87	7.83±2.94	0.879

Table 2 Follow-up outcome measure changes of both groups at 4 and 24 weeks

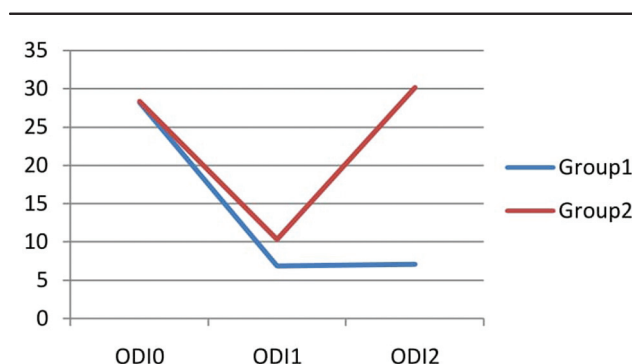
Outcome scales	Groups	Baseline (0 weeks)	4 weeks	P value (4 vs. 0 weeks)	24 weeks	P value (24 vs. 0 weeks)
VAS	I	6.67±0.89	3.42±0.71	<0.001	2.83±0.79	<0.001
	II	6.80±1.05	4.53±1.16	<0.05	6.21±1.35	NS
	P value ¹	0.399				
VRS	I	5.97±1.08	3.39±0.92	<0.001	2.76±0.74	<0.001
	II	6.11±1.32	4.47±0.89	<0.05	5.99±1.47	NS
	P value ¹	0.210				
RMQ	I	16.14±2.33	5.41±1.33	<0.001	6.02±2.07	<0.001
	II	16.50±2.37	9.52±1.91	<0.001	18.10±3.63	NS
	P value ¹	0.334				
ODI	I	28.20±3.43	6.81±1.94	<0.001	10.30±2.12	<0.001
	II	28.31±4.01	7.02±1.58	<0.001	30.11±6.29	NS
	P value ¹	0.852				

ODI, Oswestry Disability Index; RMQ, Roland Morris Disability Questionnaire; VAS, visual analog scale; VRS, verbal rating scale.

* $P<0.05$, significant. ** $P<0.001$, highly significant. ¹ P value less than 0.05.

Figure 3

The mean value of Roland Morris Disability Questionnaire (RMQ) of the two groups.

Figure 4

The mean value of Oswestry Disability Index (ODI) of the two groups.

The data showed that O_2O_3 combined with physical therapy in group I was effective in the treatment of pain and dysfunction associated with CLBP during treatment and after long-term follow-up, but group II patients treated by physical therapy alone exhibited pain and dysfunction improved only during treatment and showed recurrence at long-term follow-up.

Our results were consistent with the study done by Morelli *et al.* [12], which was done to compare the effectiveness of two therapeutic methods: the O_2O_3 paravertebral lumbar infiltration and the diathermy with exercises for CLBP treatment. They found that patients treated with paravertebral O_2O_3 therapy recorded a greater improvement, both from the first to the last session and during the re-evaluation after 3 months, showing only mild worsening. So, they concluded that the O_2O_3 therapy has a greater healing effect, which preserves over time.

Most of the studies that combined various physical therapy agents with the exercise therapy for CLBP had found significant short- and medium-term improvements in the parameters studied but not in long-term follow-up [4–6].

Many studies ascertained the effectiveness of intramuscular–paravertebral O_2O_3 injection in CLBP therapy like Paoloni *et al.* [13]. They conducted a multicenter, randomized, double-blind simulated therapy-controlled trial where 36 patients received intramuscular–paravertebral O_2O_3 injections, whereas 24 received simulated lumbar intramuscular–paravertebral injections with false needle. Patients who received O_2O_3 had significant lower pain scores compared with patients who received simulated therapy. A significant difference between the two groups in the percentage of cases who had become pain free (6 vs. 33%, $P < 0.05$) was observed at a medium follow-up of 6 months.

Moreover, Melchionda *et al.* [14] reported the results of a matched pair study between paravertebral lumbar O_2O_3 injections versus anti-inflammatory analgesic drugs. They had 80% success rate for O_2O_3 treatment at 6-month follow-up versus 50% for the anti-inflammatory analgesic drug group.

Our results were also supported by that of Zambello *et al.* [9] which included 351 patients with chronic irradiating LBP over sciatic nerve and failure to respond to medical treatment. They were randomly assigned into two groups: group I ($n=171$) was treated by epidural steroid injection and group II ($n=180$) by ozone into the paravertebral muscle. The clinical outcome was assessed in the short term (3 weeks) and long term (6 months). They also reported that ozone therapy has a higher success rate, is safe, and is considered the first choice of treatment in patient's refractory to conventional management.

More recently, Biazzo *et al.* [15] confirmed efficacy of intramuscular ozone injections in CLBP. According to their result, 109 patients underwent intramuscular–paravertebral lumbar injections of ozone for LBP, and then all patients were retrospectively evaluated with VAS and ODI scale. They obtained a reduction of 2.3 points on the VAS scale and 9% on the ODI score after treatment. So, they suggested ozone application in CLBP as first choice to replace intradiscal computed tomographic-guided infiltrations and to avoid or delay surgery.

Conclusion

Treatment of CLBP is a major concern, and O_2O_3 intramuscular lumbar paravertebral injections combined with physical therapy, which are minimally invasive, seem to safely and effectively relieve pain, as well as reduce disability.

O₂O₃ has a healing effect, which preserves over time, but physical therapy alone leads to some relapses after a few months.

The addition of O₂O₃ treatment over the traditional physical therapy for management of CLBP can offer significantly longer improvements in pain management and functional status in these patients, increasing the pain-free period.

Recommendations

Further studies with long-term follow-up periods and other combination therapies are needed to evaluate the extended effect of the minimally invasive intramuscular ozone injections in treating patients with chronic mechanical LBP.

Financial support and sponsorship

Nil.

Conflicts of interest

There are no conflicts of interest.

References

- Di Cesare A, Giombini A, di Cesare M, Ripani M, Vulpiani M, Saraceni V. Comparison between the effects of trigger point mesotherapy versus acupuncture points mesotherapy in the treatment of chronic low back pain: a short term randomized controlled trial. *Complement Ther Med* 2011; 19:19–26.
- Sostres C, Gargallo C, Arroyo M, Lanas A. Adverse effects of non-steroidal anti-inflammatory drugs (NSAIDs, aspirin and coxibs) on upper gastrointestinal tract. *Best Pract Res Clin Gastroenterol* 2010; 24:121–132.
- Kamali F, Panahi F, Ebrahimi S, Abbasi L. Comparison between massage and routine physical therapy in women with sub acute and chronic nonspecific low back pain. *J Back Musculoskeletal Rehabil* 2014; 27:475–480.
- Atalay N, Sahin F, Atalay A, Akkaya N. Comparison of efficacy of neural therapy and physical therapy in chronic low back pain. *Afr J Tradit Complement Altern Med* 2013; 10:431–435.
- Nadler S, Steiner D, Erasala G, Hengehold D, Hinkle R, Beth M, *et al.* Continuous low-level heat wrap therapy provides more efficacy than ibuprofen and acetaminophen for acute low back pain. *Spine* 2002; 27:1012–1017.
- Mayer J, Ralph L, Look M, Erasala G, Verna J, Matheson L, Mooney V. Treating acute low back pain with continuous low-level heat wrap therapy and/or exercise: a randomized controlled trial. *Spine J* 2005; 5: 395–403.
- Apuzzo D, Giotti C, Pasqualetti P, Ferrazza P, Soldati P, Zucco G. An observational retrospective/horizontal study to compare oxygen-ozone therapy and/or global postural re-education in complicated chronic low back pain. *Funct Neurol* 2014; 29:31–39.
- Magalhaes F, Dotta L, Sasse A, Teixeira M, Fonoff E. Ozone therapy as a treatment for low back pain secondary to herniated disc: a systematic review and meta-analysis of randomized controlled trials. *Pain Physician* 2012; 15:E115–E129.
- Zambello A, Fara B, Tabaracci G, Bianchi M. Epidural steroid injection vs paravertebral O₂O₃ infiltration for symptomatic herniated disc refractory to conventional treatment. A prospective randomized study. *Rivista Italiana di Ossigeno-Ozonoterapia* 2006; 5:123–127.
- Roland MO, Moris RW. A study of the natural history of back pain. Part 1: development of a reliable and sensitive measure of disability in low back pain. *Spine* 1983; 8:141–144.
- Fairbank JC. Physiotherapy 1981; 66(8): 271–273, Hudson-Cook. In: Jenner R, editors. *Back pain: new approaches to rehabilitation & education*. Manchester, UK: Manchester University Press; 1989. pp. 187–204.
- Morelli L, Bramani S, Cantaluppi M, Pauletto M, Scuotto A. Comparison among different therapeutic techniques to treat low back pain: a monitored randomized study. *Ozone Ther* 2016; 1:17–20.
- Paoloni M, di Sante L, Cacchio A, Apuzzo D, Marotta S, Razzano M, *et al.* Intramuscular oxygen-ozone therapy in the treatment of acute back pain with lumbar disc herniation: a multicenter, randomized, double-blind, clinical trial of active and simulated lumbar paravertebral injection. *Spine* 2009; 34:1337–1344.
- Melchionda D, Milillo P, Manente G, Stoppino L, Macarini L. Treatment of radiculopathies: a study of efficacy and tolerability of paravertebral oxygen-ozone injections compared with pharmacological anti-inflammatory treatment. *J Biol Regul Homeost Agents* 2012; 26:467–474.
- Biazzo A, Corriero A, Confalonieri N. Intramuscular oxygen-ozone therapy in the treatment of low back pain. *Acta Biomed* 2016; 87:1–6.