

Neuromuscular ultrasound in ulnar neuropathy at the elbow: correlation with electrodiagnostic studies

Esraa Muhammad Bastawy, Naglaa Ali Gad Allah, Ola Abd El Nasser, Eman Ahmed Tawfik

Physical Medicine, Rheumatology and Rehabilitation. Faculty of Medicine, Ain Shams University, Egypt

Correspondence to Esraa Muhammad Bastawy, MB, BCh, Faculty of Medicine, Ain Shams University, Rheumatology, Rehabilitation and Physical Medicine Department, Egypt.
Tel: 01154023786;
e-mail: esraa.m.bastawy@gmail.com

Received 8 March 2019

Accepted 14 March 2019

Egyptian Rheumatology & Rehabilitation
2019, 46:92–100

Introduction

Ulnar nerve entrapment is the second most common entrapment neuropathy in the upper limb after carpal tunnel syndrome, and, if left untreated, it may lead to significant functional impairment and disability.

Objective

The aim of this study was to perform clinical, electrodiagnostic (EDX), and neuromuscular ultrasound assessment for patients with ulnar neuropathy at the elbow, to determine the possible roles of neuromuscular ultrasound in the localization of the neuropathy, in the detection of its possible etiologies and in the determination of its severity.

Patients and methods

A sample of 15 (22 elbows) patients was recruited and subjected to full medical history, neurological assessment, EDX studies, and neuromuscular ultrasound examination. Ten (20 elbows) age-matched and sex-matched healthy volunteers were also recruited and served as a control group.

Results

This study revealed significantly enlarged ulnar nerve cross-sectional area (CSA) at the ulnar groove and below the elbow and supracondylar sites in patients compared with the control group. receiver-operating characteristic curve analysis revealed high diagnostic accuracy of the absolute CSA at the ulnar groove, and below the elbow and supracondylar sites, with an area under the curve of 0.8, 0.8, and 0.9, respectively, and the cutoff values were >9, >8, and >8, respectively. The area under the curve for the 'maximum CSA/midforearm CSA ratio' was 0.9, with a cutoff value of more than 1.3.

Conclusion

Our study data suggest that neuromuscular ultrasound (NMUS) examination may play a potentially important role in the assessment of ulnar neuropathy at the elbow. It can localize the lesion and disease severity, and it can differentiate between patients and controls, given its high diagnostic ability. Abnormalities in ultrasonographic features of ulnar nerve entrapment with regard to CSA and ratio between 'maximum CSA and midforearm CSA' at the elbow was correlated with EDX findings.

Keywords:

cubital tunnel syndrome, electrodiagnosis, nerve cross-sectional area, neuromuscular ultrasound, ulnar neuropathy at the elbow

Egypt Rheumatol Rehabil 46:92–100

© 2019 Egyptian Society for Rheumatology and Rehabilitation
1110-161X

Introduction

Ulnar nerve entrapment at the elbow is the second most prevalent entrapment neuropathy of the upper limb, after median nerve entrapment at the carpal tunnel [1].

Repeated friction of the nerve and its contact with the bony surface can cause neuritis and subsequent functional loss [2].

The diagnosis of cubital tunnel syndrome is typically based on clinical symptoms and signs, and confirmed by electrodiagnostic (EDX) studies [3].

EDX studies determine the underlying pathology, whether axonal, demyelinating, or mixed, localize the

level of entrapment, and assess chronicity and severity, which in turn determine the prognosis. However, EDX studies sometimes fail to localize the lesion and cannot evaluate the architecture or the anatomical aspect of the nerves and its surrounding structures. Moreover, they are sometimes accompanied by a substantial rate of false-negative and false-positive results [4].

Neuromuscular ultrasound has emerged as an additional diagnostic tool for neuromuscular disorders. It has

This is an open access journal, and articles are distributed under the terms of the Creative Commons Attribution-NonCommercial-ShareAlike 4.0 License, which allows others to remix, tweak, and build upon the work non-commercially, as long as appropriate credit is given and the new creations are licensed under the identical terms.

proven itself as a valuable complementary tool to EDX studies. While EDX studies assess the functional aspect of the nerve, neuromuscular ultrasound evaluates the anatomical aspect. Nowadays, ultrasound is able to identify successfully almost all main nerve trunks running in the limbs [5].

Several studies have been performed to evaluate the ultrasound findings in ulnar neuropathy. These studies have shown that focal enlargement of the ulnar nerve at the elbow is a relevant component of ulnar neuropathy and thus can be helpful as an adjunct to EDX studies in detecting patients with cubital tunnel syndrome [6].

Ultrasonography of the elbow offers a number of advantages over other imaging tools such as MRI, including being less time consuming, having no radiation, facilitates easy comparison with the other side, has a better cost-effectiveness ratio, superior spatial resolution and dynamic capability [7].

Most of the published studies focused on the ultrasonographic appearance of the ulnar nerve in ulnar neuropathy at the elbow but few addressed its correlation with EDX studies.

Objective

The objectives of this study were to determine the possible roles of neuromuscular ultrasound in localizing the neuropathy and in detecting its possible etiologies, and to correlate the sonographic findings with the EDX findings.

Patients and methods

This study was carried out on 15 (22 elbows) patients who presented to the outpatient clinic or to the Electrodiagnostic Unit of the Physical Medicine, Rheumatology and Rehabilitation Department at Ain Shams University Hospitals. Ten (20 elbows) apparently healthy individuals of matched age and sex were recruited from the same hospital and served as a control group to compare neuromuscular ultrasound findings in patients versus controls.

Inclusion criteria: patients with characteristic symptoms and signs of ulnar neuropathy at the elbow were included.

The clinical diagnosis of cubital tunnel syndrome was made if the patient complained of pain, numbness and or tingling in the ring and little fingers, especially if it increased with elbow flexion and/or weakness of the

ulnar-innervated muscles, with or without positive Tinel's sign.

All patients were subjected to the following:

- (1) Full medical history with special emphasis on the onset, course, and duration of the patient's symptoms, distribution of paresthesia, tingling, and numbness, distribution of weakness if any, and any functional limitations during activities of daily living.
- (2) Clinical examination, which included general examination and full neurological and musculoskeletal examination.
- (3) Plain radiographs of the elbow joint to assess for any deformities, degenerative changes, or soft-tissue calcifications.
- (4) Nerve conduction studies:

The following EDX protocol [8] was followed:

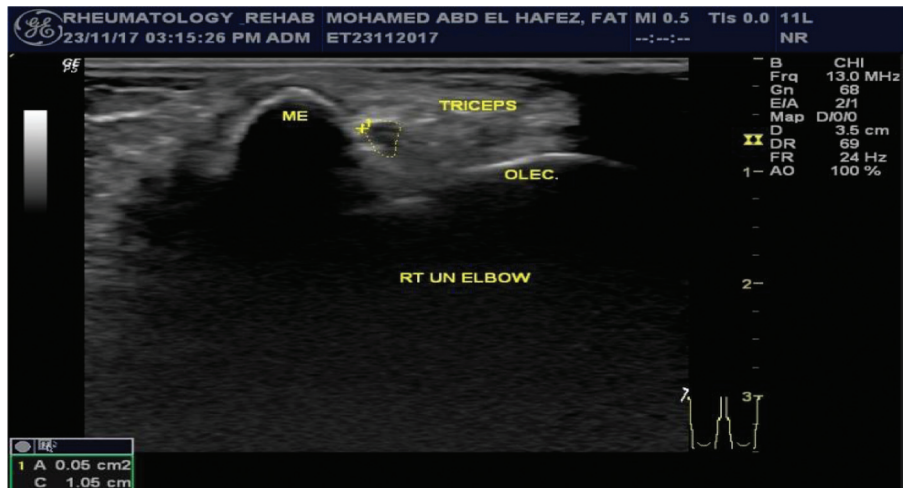
- (a) Motor nerve conduction study of the ulnar nerve, with recording from the abductor digiti minimi and stimulation at the wrist, below the elbow (3–4 cm distal to the medial epicondyle) and above the elbow (10 cm from the below-elbow stimulation site). The study was repeated with recording from the first dorsal interosseus, performing inching technique and mixed and sensory conduction studies if EDX demonstrated axonal features alone, with no evidence of focal demyelination at the elbow.
- (b) Sensory conduction study of the ulnar nerve with recording from the ring and little fingers, and stimulation at the wrist, below the elbow and above the elbow.
- (c) Motor and sensory conduction studies of the median nerve, and sensory conduction study of the radial nerve, to exclude more widespread polyneuropathies and thoracic outlet syndrome.
- (d) F-wave study of the ulnar and median nerves to assess the proximal roots.

The patient was diagnosed as having EDX-proven ulnar neuropathy at the elbow if one of the following patterns was found:

Pattern 1: Ulnar neuropathy at the elbow with demyelinating and axonal features in the form of the following (and they are):

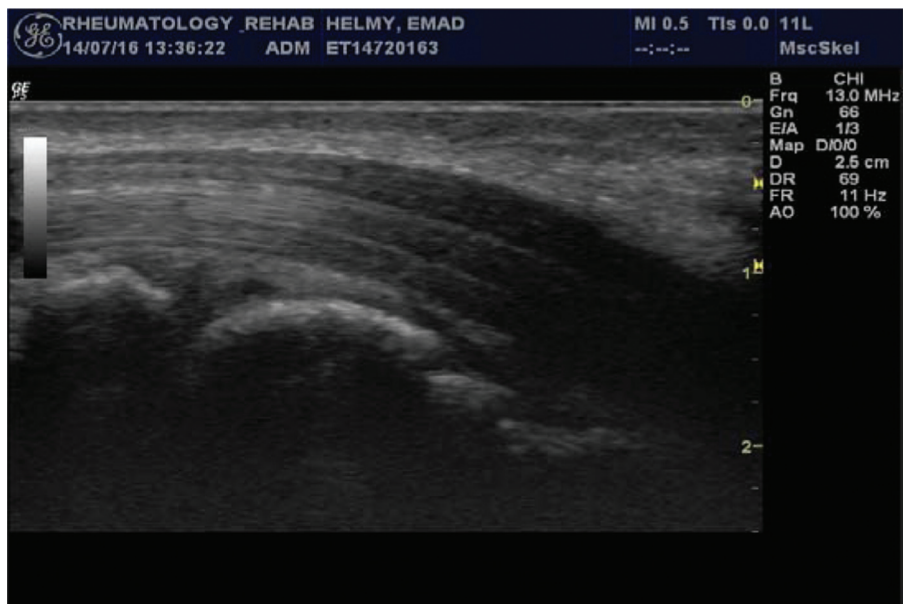
- (a) Low ulnar sensory nerve action potential ($<15 \mu\text{v}$ at the below-elbow or $14 \mu\text{v}$ above-elbow sites).
- (b) Normal or low-amplitude ulnar compound muscle action potential (CMAP) [$<4 \text{ mv}$ with normal or slightly prolonged distal latency ($>3.4 \text{ ms}$)].

Figure 1



Shows normal transverse scan at the ulnar groove. ME, medial epicondyle; OLEC, olecranon.

Figure 2



Shows longitudinal scanning of the ulnar nerve with normal appearance.

- (c) Unequivocal evidence of demyelination at the elbow (conduction block and/or slowing $>10-11$ m/s across the elbow compared with the forearm segment, in the flexed elbow position).

Pattern 2: Ulnar neuropathy at the elbow with pure demyelinating features:

- (a) Normal distal ulnar sensory nerve action potential and CMAP amplitudes and latencies.
- (b) Unequivocal evidence of demyelination at the elbow (conduction block and/or slowing $>10-11$ m/s across the elbow

compared with the forearm segment, in the flexed elbow position).

- (5) Neuromuscular ultrasound of the ulnar nerve (was performed for all patients and controls).

The study was performed using LOGIQ P5 ultrasound system (General Electric Company, New York, New York, USA) and 13 MHz linear array transducer. The ulnar nerve was imaged in two views: axial (Fig. 1) and longitudinal (Fig. 2). In the axial view, the nerve was traced from the wrist (level of Guyon's canal) to the midarm level and was assessed as regards size, echogenicity, vascularity and mobility.

Moreover, the surrounding structures were screened for any abnormalities, or anatomical variants like accessory muscles.

Nerve cross-sectional area (CSA) was measured at the site of maximal enlargement, which was at either the ulnar groove or the below elbow or supracondylar sites. The ratio between the area of maximal enlargement/midforearm CSA was calculated. The CSA was measured using the trace function by tracing the nerve just inside its hyperechoic rim. Care was taken during scanning to ensure orthogonal orientation of the probe at all times and that least pressure was exerted by the probe. Echotexture was assessed by observing and recording any change including hypoechogenicity of the nerve, loss of typical honeycomb appearance, focal enlargement of one fascicle, diffuse enlargement of all fascicles or change in the echotexture of the outer epineurium.

Mobility was assessed by placing the probe at the ulnar groove in the axial view with the elbow extended with the release of any pressure by the probe, and then the patient was asked to actively and gradually flex the elbow to observe any subluxation or dislocation of the nerve. The nerve was considered subluxated if the ulnar nerve moved anteriorly to the apex of the medial epicondyle but did not snap over the medial epicondyle, and was considered dislocated if the ulnar nerve snapped completely over the medial epicondyle during flexion with reduction to normal position in extension.

Statistical analysis

Statistical analysis was conducted and analyzed using statistical package for the social sciences program

(SPSS) software version 20.0 (IBM SPSS statistics for windows, version 20.0 Armonk, NY: IBM corp., SPSS inc., IBM corporation). Quantitative data were expressed as mean±SD. Student's *t*-test was used for comparison of two means. Paired *t*-test was used to determine whether the mean difference between two sets of observations was zero, and χ^2 -test was used for testing relationships between categorical variables.

The level of significance was taken at *P* value up to 0.05. Descriptive statistics were performed for quantitative data as minimum and maximum of the range as well as the mean and the SDs for quantitative parametric data, while it was performed for qualitative data as number and percentage. A receiver-operating characteristic (ROC) analysis was performed to determine the sensitivity and the specificity of the ulnar nerve diameter and the amplitude of ulnar nerve conduction studies.

Correlation studies were performed using Pearson's correlation test (*r*); *P* value equal to or less than 0.05 was considered a statistically significant difference.

Results

This table shows that the ulnar nerve CSA was significantly enlarged in patients compared with controls at below-elbow [between the two heads of flexor carpi ulnaris (FCU)], ulnar groove and above-elbow (supracondylar) sites ($P \leq 0.05$; Table 1). Moreover, the ratio between maximum CSA and midforearm CSA was significantly higher in patients compared with the controls ($P \leq 0.05$; Table 1).

Table 1 Comparison of ulnar nerve cross-sectional area between patients and control groups

Ulnar nerve cross-sectional area by ultrasound	Patients (N=22)	Control (N=10)	<i>t</i> -Test	<i>P</i> value
Guyon's canal (mm ²)				
Mean±SD	6.09±2.24	5.45±1.23	1.277	0.265
Range	4–13	4–8		
Midforearm (mm ²)				
Mean±SD	6.64±2.59	5.80±1.28	1.701	0.200
Range	4–14	4–8		
Below the elbow (between two heads of FCU) (mm ²)				
Mean±SD	8.82±2.97	5.95±1.43	15.374	<0.001**
Range	5–16	4–8		
Ulnar groove				
Mean±SD	12.45±5.93	6.50±1.47	19.038	<0.001**
Range	5–27	4–9		
Supracondylar area				
Mean±SD	8.95±3.26	5.80±1.28	16.407	<0.001**
Range	4–17	4–8		
Ratio between maximum cross-sectional area and midforearm				
Mean±SD	2.06±1.01	1.13±0.09	16.980	<0.001**
Range	1.07–4.25	1–1.25		

* $P > 0.05$ is non-significant. ** $P \leq 0.01$, highly significant. FCU, flexor carpi ulnaris.

There was a statistically significant positive correlation between ulnar nerve CSA values at both the ulnar groove and below the elbow and the distal motor latency (DML), whereas there was a statistically significant negative correlation between ulnar CSA values at below elbow, ulnar groove and supracondylar sites with below-elbow amplitude. There was a statistically significant negative correlation between ulnar CSA values at the below elbow and ulnar groove sites with each of the following EDX parameters: DML and CMAP distal amplitude and conduction velocity. There was also a highly significant negative correlation between ulnar CSA at the ulnar groove and above-elbow amplitude ($P \leq 0.05$; Table 2)

Table 3 shows the correlation between nerve conduction parameters and ratio between 'maximum CSA/midforearm' and shows a statistically significant difference between the ratio and the distal amplitude, below-elbow amplitude, above-elbow amplitude and conduction velocity across the forearm.

We did not find a statistically significant correlation between EDX parameters and ulnar nerve CSA at the midforearm and Guyon's canal ($P > 0.05$).

There was a statistically significant positive correlation between the disease duration and the distal motor latency, ulnar nerve CSA at the ulnar groove, and

Table 3 Correlation study between nerve conduction studies and the ratio between the maximum cross-sectional area/midforearm cross-sectional area

Nerve conduction parameters	Ratio between maximum cross-sectional area and midforearm cross-sectional area	
	R	P value
Distal motor latency	0.256	0.250
Distal amplitude	-0.540	0.011*
Below-elbow amplitude	-0.519	0.013*
Above-elbow amplitude	-0.608	0.003*
Conduction velocity across elbow	-0.305	0.167
Conduction velocity across forearm elbow	-0.428	0.047*

* $P \leq 0.05$, significant.

Table 2 Correlation between ulnar nerve cross-sectional area at the ulnar groove and the nerve conduction parameters in the patients' group

Nerve conduction parameters	Below the elbow (between two heads of FCU)		Ulnar groove cross-sectional area		Supracondylar	
	r	P value	r	P value	r	P value
Distal motor latency	0.481	0.024*	0.543	0.009*	0.258	0.246
Distal amplitude	-0.473	0.026*	-0.607	0.003*	-0.472	0.027
Below-elbow amplitude	-0.448	0.037*	-0.561	0.007*	-0.443	0.039*
Above-elbow amplitude	-0.316	0.152	-0.712	<0.001**	-0.400	0.065
Conduction velocity above elbow	-0.576	0.005*	-0.562	0.007*	-0.342	0.120
Conduction velocity below elbow	-0.408	0.039*	-0.582	0.005*	-0.288	0.194

* $P \leq 0.05$ significant. ** $P \leq 0.01$, highly significant. FCU, flexor carpi ulnaris.

Table 4 Correlation between disease duration and nerve conduction parameters and ulnar nerve cross-sectional areas in the patients' group

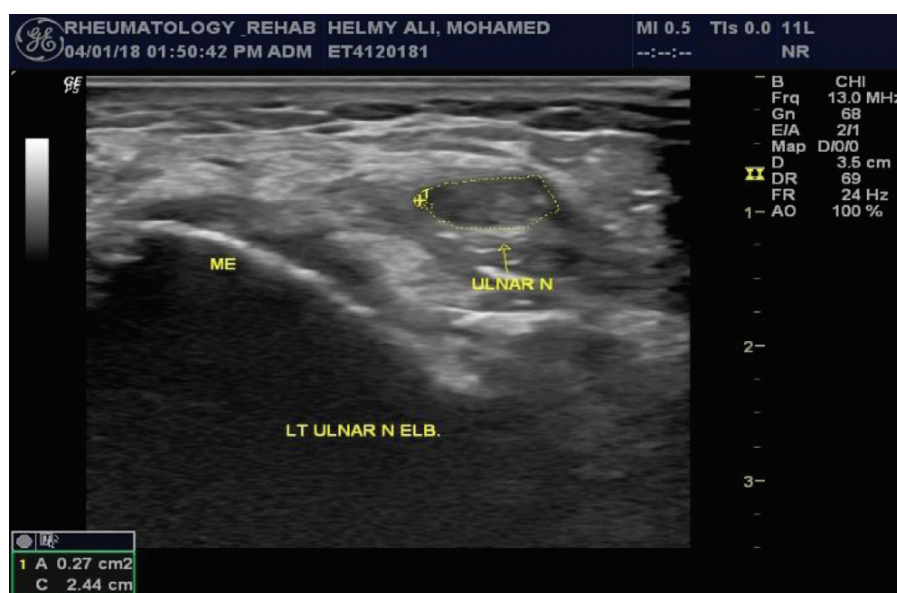
Nerve conduction parameters	Disease duration (years)	
	r	P value
Distal motor latency	0.659	<0.001**
Distal amplitude	-0.463	0.030*
Below-elbow amplitude	-0.343	0.118
Above-elbow amplitude	-0.606	0.003*
Conduction velocity through the elbow	-0.393	0.046*
Conduction velocity through the forearm	-0.490	0.021*
Ulnar nerve cross-sectional areas at different levels by ultrasound		
Guyon's canal	-0.116	0.606
Midforearm	0.050	0.824
Below the elbow (between two heads of FCU)	0.095	0.676
Ulnar groove	0.591	0.004*
Supracondylar	0.098	0.663
Ratio between maximum cross-sectional area and midforearm	0.399	0.047*

FCU, flexor carpi ulnaris. * $P \leq 0.05$ significant. ** $P \leq 0.01$, highly significant.

Table 5 Results of receiver-operating characteristic curve analysis of the absolute ulnar nerve cross-sectional areas and cross-sectional area ratio

Ulnar nerve cross-sectional area by ultrasound	Cutoff	Sensitivity (%)	Specificity (%)	PPV (%)	NPV (%)	Area under the curve (%)
Guyon's canal	>7	27.3	95	85.7	54.3	55.8
Midforearm	>6	50	70	64.7	56	57.5
Below the elbow (between the two heads of FCU)	>8	59.1	100	100	69	80.8
Ulnar groove	>9	72.7	100	100	76.9	82.0
Supracondylar	>8	59.1	100	100	69	92.2
Maximum cross-sectional area and midforearm	>1.3	86.4	85	86.4	85	92.5

FCU, flexor carpi ulnaris; NPV, negative predictive value; PPV, positive predictive value.

Figure 3

A transverse scan of the left ulnar nerve at the supracondylar level showing ulnar nerve entrapment. The nerve shows normal echotexture. The nerve Cross sectional area (CSA) is 0.27 cm².

the ratio between maximum CSA and midforearm CSA ($P \leq 0.05$; Table 4), whereas there was significant negative correlation between disease duration and the distal amplitude, above-elbow amplitude, conduction velocity across the elbow, and the conduction velocity along the forearm ($P \leq 0.05$; Table 4).

In contrast, there was no significant correlation between the disease duration and below-elbow amplitude of ulnar nerve CMAP, ulnar nerve CSA at the Guyon's canal, midforearm, and below-elbow and supracondylar areas ($P > 0.05$; Table 4).

As regards the sensitivity and diagnostic accuracy of the ulnar nerve CSA, is shown in Table 5, testing the diagnostic accuracy of the ulnar nerve CSAs at different levels and the CSA, using the ROC curve, revealed highest area under the curve for the CSA ratio, CSA above the elbow, CSA at

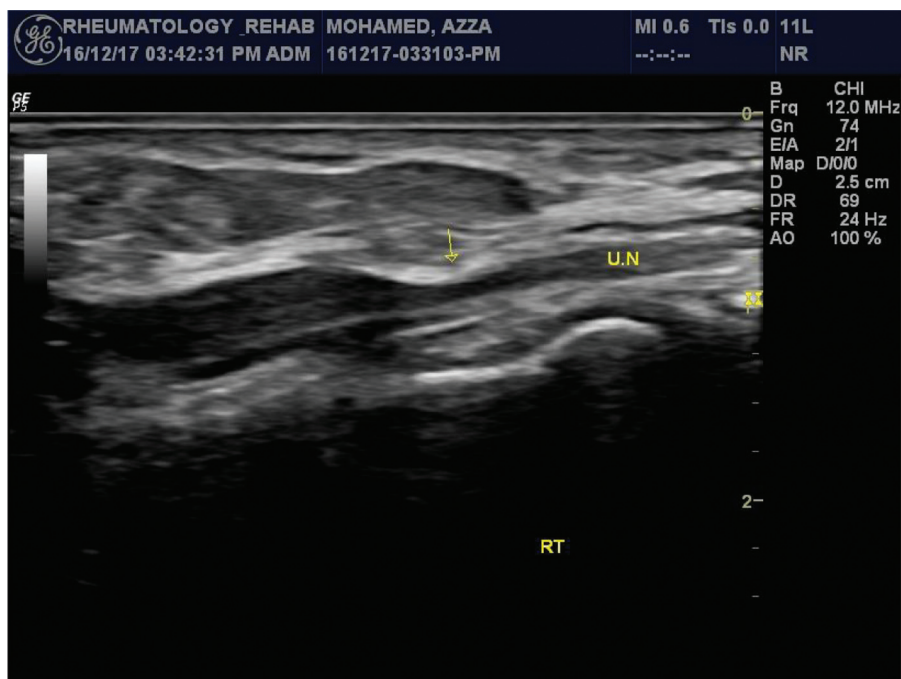
the ulnar groove, and CSA below the elbow (0.9, 0.9, 0.8, and 0.8, respectively). The cut-off value of the 'maximum CSA/midforearm CSA ratio' to differentiate between patients and controls was 1.3, with a sensitivity of 86.4% and specificity of 85%. The positive predictive value was 86.4%, and the negative predictive value was of 85% (Table 5).

Ultrasound was able to determine the site of pathology, which was confirmed in transverse (Fig. 3), as well as longitudinal views (Fig. 4).

Discussion

Ulnar neuropathy at the elbow is the second most common upper limb entrapment. Proper evaluation of ulnar neuropathy is strongly recommended to determine the optimum management, because incomplete improvement may have functional, psychological and social disabilities.

Figure 4



A longitudinal scanning of Right Ulnar nerve entrapment at the ulnar groove: arrow points to the site of entrapment. UN, ulnar nerve.

Although the electrophysiological tests are important indispensable tools in the diagnostic workup of ulnar neuropathy at the elbow, they have some limitations.

The aim of this study was to assess the value of neuromuscular ultrasound in ulnar neuropathy at the elbow and assess its correlation with the EDX studies.

As regards ultrasound findings, the mean CSA of the ulnar nerve in our control group was 5.45 mm² at the Guyon's canal, 5.8 mm² at the midforearm, 5.95 mm² at the cubital tunnel, 6.50 at the ulnar groove and 5.80 mm² at the supracondylar area. Our measurements agree with the published reference values of ulnar nerve CSA [9].

Mean values of 'maximum enlargement/midforearm' CSA ratio in our study was 1.13, and the cutoff value of the CSA ratio was 1.3. This is quite similar to the results obtained by Cartwright and Walker [10], who measured CSA at the cubital tunnel and another nonaffected site and calculated the ratio between them. The cutoff value was 1.4 in their study.

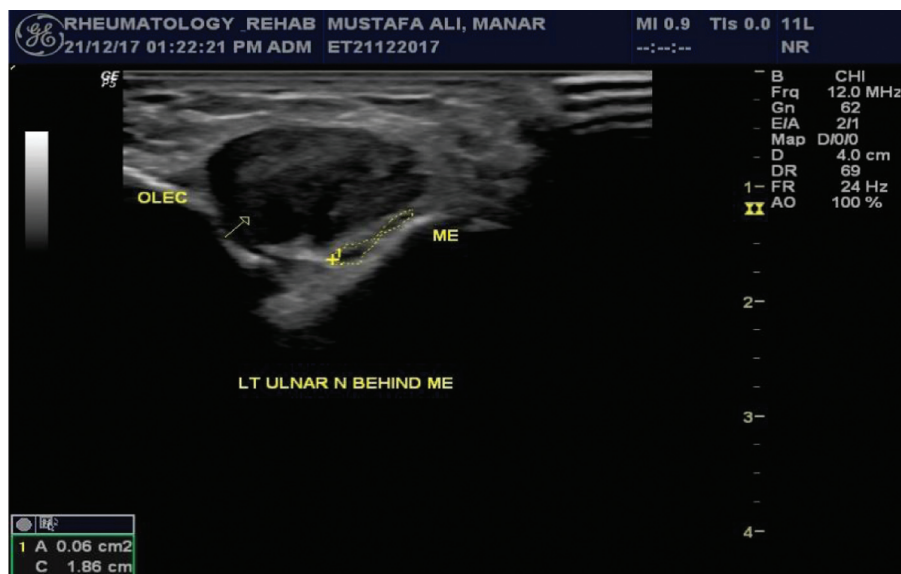
Moreover, Gruber *et al.* [11] found a cutoff value of CSA ratio between "CSA of maximum enlargement/midhumeral CSA" to be 1.4; although they used different methodology and number of patients, the CSA area ratio is similar to ours.

This study included fewer patients, and we measured the CSA ratio and the absolute CSA differently. We measured the ratio between CSA at maximum enlargement and midforearm. However, Gruber *et al.* [11] calculated the CSA ratio between the cubital tunnel and the midhumeral area and found a CSA ratio more than 1.4 to be diagnostic for cubital tunnel with a specificity of more than 95.

In this study, we found a significant difference in CSA at the ulnar groove, cubital tunnel and supracondylar levels between patients and control groups. The CSA was significantly larger in patients compared with the controls. Similarly, Gruber *et al.* [11] also found a significant difference in CSA at the ulnar groove, cubital tunnel and supracondylar levels in their patients compared with their controls. In contrast, we did not find a significant difference in CSA at Guyon's canal and the midforearm between our patients and controls, which denotes that, in patients with ulnar nerve entrapment, the enlargement is focal at the elbow region.

In this study, there was a negative correlation between the maximum ulnar nerve CSA/midforearm CSA ratio and CMAP amplitude and conduction velocity (CV), whereas there was no significant correlation between CSA ratio and the DML. The negative correlation between CSA and amplitude and CV denote that nerve

Figure 5



A transverse scan of the left ulnar nerve behind the medial epicondyle. A large mass (Arrow) measuring 1.46×2.46 cm with heterogenous echogenicity compressing the ulnar nerve at the ulnar groove. ME, medial epicondyle; OLEC, olecranon. The nerve cross sectional area measures 0.06 cm².

enlargement is related to the degree of axonal affection and demyelination, and thus neuromuscular ultrasound (NMUS) can be useful in the assessment of severity of entrapment.

There was a statistically significant positive correlation between ulnar nerve CSA values at both the ulnar groove and below the elbow and the DML; this means that, as the CSA increases, the DML prolongs, whereas there was a statistically significant negative correlation between ulnar CSAs at below the elbow, ulnar groove and supracondylar sites with below-elbow amplitude. There was a statistically significant negative correlation between ulnar CSA at below the elbow and ulnar groove sites with each of the following EDX parameters: DML, CMAP distal amplitude and conduction velocity. There was also a highly significant negative correlation between ulnar CSA at the ulnar groove and above-elbow amplitude, which denotes that the nerve enlarges as the amplitude decreases and is related somehow to the degree of axonal loss. This agrees with the results obtained by Volpe and colleagues who found a significant correlation between maximum CSA and severity estimated by nerve conduction velocity (NCVs).

In contrast, there was no significant correlation between the disease duration and below-elbow amplitude of ulnar nerve CMAP, ulnar nerve CSA at the Guyon's canal, midforearm, and below-elbow and supracondylar areas ($P > 0.05$).

The ultrasound detected changed echogenicity (anechoic) of the ulnar nerve in one of 22 elbows, in three abnormal mobility cases (two subluxated and one dislocated), in two patients with accessory anconeus epitrochlears muscle, and in one patient who had a compressing mass at the ulnar groove (Fig. 5).

ROC curve results demonstrated high diagnostic ability of absolute CSA and the ratio between 'maximum enlargement/midforearm CSA', making it a useful tool to differentiate between patients and controls.

Limitations of the study include the small number of patients in each group and the lack of follow-up of the patients to track the sonographic and EDX changes postconservative or surgical management. Another limitation is that we did not assess the sonographic changes in the ulnar-innervated muscles.

Conclusion

Our limited data suggest that NMUS examination plays a potentially important role in the assessment of ulnar neuropathy at the elbow; it can localize the lesion and detects the site of maximal enlargement, which could be of value if surgical intervention is required. It detected changed echogenicity and mobility, giving an idea about the ongoing pathology. In addition, it may reveal the causative pathology such as accessory anconeus epitrochlears muscle or compressing masses. On the basis of

ROC curve analysis, its diagnostic ability is high with good sensitivity and specificity and thus is able to differentiate between patients and healthy individuals. Moreover, it correlates with the parameters of NCS and thus can give a clue about severity of the entrapment.

Financial support and sponsorship

Nil.

Conflicts of interest

There are no conflicts of interest.

References

- 1 Beekman R, van Der Plas JP, Uitdehaag BM, Schellens RL, Visser LH. Clinical, electrodiagnostic, and sonographic studies in ulnar neuropathy at the elbow. *Muscle Nerve* 2004; 30:202–208.
- 2 Volpe A, Rossato G, Bottanelli M, Marchetta A, Caramaschi P, Bambara LM, *et al.* Ultrasound evaluation of ulnar neuropathy at the elbow: correlation with electrophysiological studies. *Rheumatology* 2009; 48:1098–1101.
- 3 Okamoto M, Abe M, Shirai H, Ueda N. Diagnostic ultrasonography of the ulnar nerve in cubital tunnel syndrome. *J Hand Surg Br* 2000; 25:499–502.
- 4 Miller TT, Reinus WR. Nerve entrapment syndromes of the elbow, forearm, and wrist. *Am J Roentgenol* 2010; 195:585–594.
- 5 Walker FO, Cartwright MS, Wiesler ER, Caress J. Ultrasound of nerve and muscle. *Clin Neurophysiol* 2004; 115:495–507.
- 6 Thoirs K, Williams MA, Phillips M. Ultrasonographic measurements of the ulnar nerve at the elbow: role of confounders. *J Ultrasound Med* 2008; 27:737–743.
- 7 Shahabpour M, Kichouh M, Laridon E, *et al.* The effectiveness of diagnostic imaging methods for the assessment of soft tissue and articular disorders of the shoulder and elbow. *Eur J Radiol* 2008; 65:194–200.
- 8 Preston DC, Shapiro BE. *Electromyography and Neuromuscular Disorders E-Book: Clinical-Electrophysiologic Correlations (Expert Consult-Online)*. 2012.
- 9 Kerasnoudis A, Pitarokoili K, Behrendt V, Gold R, Yoon MS. Cross sectional area reference values for sonography of peripheral nerves and brachial plexus. *Clin Neurophysiol* 2013; 124:1881–1888.
- 10 Cartwright MS, Walker FO. Neuromuscular ultrasound in common entrapment neuropathies. *Muscle Nerve* 2013 48:696–704.
- 11 Gruber H, Glodny B, Peer S. The validity of ultrasonographic assessment in cubital tunnel syndrome: the value of a cubital-to-humeral nerve area ratio (CHR) combined with morphologic features. *Ultrasound Med Biol* 2010; 36:376–382.