

# Validity of magnetic resonance image and HLA-B27 in early detection of sacroiliitis in Egyptian spondyloarthropathic patients

Rawhya R. El-Shereef<sup>a</sup>, Amal Ali<sup>a</sup>, Ayman Darwish<sup>a</sup>, Fatma Ali<sup>a</sup>, Mohammed Ibrahim<sup>b</sup>, Lamia Hamdy<sup>c</sup>

Departments of <sup>a</sup>Rheumatology and Rehabilitation, <sup>b</sup>Radiology, <sup>c</sup>Clinical Pathology, Faculty of Medicine, Minia University, Al-Minia, Egypt

Correspondence to Rawhya R. El-Shereef, MD, Department of Rheumatology and Rehabilitation, Faculty of Medicine, Minia University, Al-Minia, Egypt  
Tel: +20 109 228 9321;  
e-mail: rawhyaelsheereef@yahoo.com

**Received** 23 August 2014

**Accepted** 28 March 2015

**Egyptian Rheumatology & Rehabilitation**  
2015, 42:137–144

## Objective

The aim of this study was to compare the validity of MRI in the early detection of sacroiliitis with laboratory findings of human leukocyte antigen-B27 (HLA-B27), conventional radiography, and clinical assessment.

## Participants and methods

Sixty patients with spondyloarthropathy (group II) with duration of illness less than 2 years and 20 healthy controls (group I) were included in this study. Both groups were subjected to assessment of history, clinical examination, and laboratory investigations (erythrocyte sedimentation rate, C-reactive protein titer, rheumatoid factor, HLA-B27). Conventional radiography and MRI of the sacroiliac joints were performed. Spondyloarthropathic patients were divided according to MRI as follows: group IIA, which included patients with sacroiliitis, and group IIB, which included patients without sacroiliitis.

## Results

In our study, ankylosing spondylitis was diagnosed in 22 (36.6%) patients, followed by undifferentiated spondyloarthropathy in 12 (20%) patients, reactive arthritis in 10 (16.7%) patients, psoriatic arthropathy in 10 (16.7%) patients, and enteropathic arthropathy in six (10%) patients. Evidence of sacroiliitis was found in 66.6% (40/60) of patients by MRI, which was higher than the result obtained by plain radiography 20% (12/60). HLA-B27 positivity found in 53.3% (32/60) of patients. There was a significant difference between the two groups in HLA-B27 and radiological sacroiliitis; there was no sacroiliitis in the control group. MRI showed sacroiliitis even in patients with no inflammatory back pain. There was a highly statistically significant difference between patient subgroups in disease duration ( $P = 0.001$ ) and primary complaints and clinical sacroiliitis ( $P = 0.001$ ).

## Conclusion

MRI is the preferred modality in the detection of early sacroiliitis in spondyloarthropathy and HLA-B27 positivity is a highly useful predictor of early sacroiliitis

## Keywords:

HLA-B27, MRI, sacroiliitis, spondyloarthropathies

Egypt Rheumatol Rehabil 42:137–144

© 2015 Egyptian Society for Rheumatology and Rehabilitation

1110-161X

## Introduction

Spondyloarthropathy (SPA) are a group of interrelated rheumatic conditions including ankylosing spondylitis (AS), reactive arthritis, psoriatic arthritis, and SPA associated with inflammatory bowel disease (Crohn's disease or ulcerative colitis), undifferentiated spondyloarthropathy (USPA), and juvenile-onset spondyloarthritis [1]. Men, who are slightly more frequently affected than women, have more radiographic progression [2]. Spondyloarthritides are characterized by sacroiliitis with inflammatory back pain, peripheral arthropathy, absence of rheumatoid factor and subcutaneous nodules, enthesitis, and extra-articular or extraspinous involvement, including the eyes, heart, lung, and skin. There is a tendency toward familial aggregation as well as varying associations with human leukocyte antigen-B27 (HLA-B27) [3]. HLA-B27 is a polymorphic form of the HLA-B molecule that is found

in only 8% of the general population worldwide [4]. Over 25 molecular subtypes of HLA-B27 have been described thus far [5]. The most common subtypes (HLA-B\*2705, HLA-B\*2702, HLA-B\*2704, HLA-B\*2707) are clearly associated with a risk for spondyloarthritis. Two subtypes of HLA-B27, HLA-B\*2706 (found in Southeast Asia) and HLA-B\*2709 (found in Sardinia), appear not to be associated with spondylitis, possibly because of amino acid differences in the 'B' pocket of the HLA antigen-binding cleft that alter the composition of peptides presented by these HLA-B27 subtypes. The other subtypes of

This is an open access article distributed under the terms of the Creative Commons Attribution-NonCommercial-ShareAlike 3.0 License, which allows others to remix, tweak, and build upon the work non-commercially, as long as the author is credited and the new creations are licensed under the identical terms.

HLA-B27 are too rare to have had disease associations established [6]. The traditional pathophysiological framework for spondyloarthritis is the arthritogenic-peptide theory, which proposes that HLA-B27 presents self-peptides that resemble pathogen-derived peptides to CD8-restricted T lymphocytes [7]. The radiographic hallmark of the group is sacroiliitis, which, when present, is useful in the diagnosis. MRI changes have now been included in the new classification criteria of early axial SPA and are now considered a major tool in the diagnosis. Over the past decade, tumor necrosis factor- $\alpha$ -blocking agents have been investigated extensively and became the main stream of therapy, providing an effective treatment to the patients [8].

## Patients and methods

### Patients

Our study was carried out in Al-Minia University Hospital. All patients were recruited from the Rheumatology outpatient clinic and the private clinics of rheumatology doctors. Our study included the following groups:

- (1) *Group I*: 20 apparently healthy volunteers as a control group.
- (2) *Group II*: 60 patients were diagnosed with SPA according to European Spondyloarthropathy Study Group (ESSG) [9]. Then, the patients were divided into two groups: those with axial SPA and those with peripheral SPA [according to the assessment in spondyloarthritis international society (ASAS) classification criteria for axial [10] or peripheral [11] SPA, respectively]. The disease duration is less than 2 years (from onset of symptoms or appearance of the first signs attributable to the disease). The patients with SPA were subdivided according to the presence of sacroiliitis by MRI as follows: group IIA, which included patients with sacroiliitis, and group IIB, which included patients without sacroiliitis. A comparison was performed between the two groups in terms of clinical, laboratory, and radiological variables.

### Exclusion criteria

Exclusion criteria were as follows:

- (1) Disease duration more than 2 years.
- (2) History of trauma or surgery to the knees, ankles, or elbows.

### Ethical considerations

The nature of the present study was explained to all patients. The laboratory and radiological procedures

represent standard care and pose no ethical conflicts. A verbal and written consent was obtained from all patients and controls.

### Methods

All patients were subjected to a full history taking, full general and musculoskeletal examination including measurements of swelling joint count, total joint count, and all provocative tests of sacroiliitis. All patients were subjected to assessment of all the following indices: Bath Ankylosing Spondylitis Disease Activity Index (BASDAI), Bath Ankylosing Spondylitis Functional Index (BASFI), Bath Ankylosing Spondylitis Metrology Index (BASMI), and Maastricht Ankylosing Spondylitis Enthesitis Score (MASSES) [12].

All patients and controls were subjected to the following laboratory and radiologic investigations:

### Laboratory investigations

Erythrocyte sedimentation rate was determined using the Westergren method. C-reactive protein (CRP) was determined using which included latex agglutination slide test for qualitative and semiquantitative determination of CRP in nondiluted serum. Rheumatoid factor was determined using the latex fixation test. HLA-B27 was determined using the qualitative two-color direct immunofluorescence method for the rapid detection of HLA-B27 antigen expression in erythrocyte-lysed whole blood using the BD FACSCanto (USA) family of flow cytometers [13].

### Radiological investigations

One hundred and sixty sacroiliac joints (SIJs) of 60 patients and 20 controls were evaluated in a blinded manner by plain radiography and enhanced MRI. Complete clinical examinations were performed for all patients before the application of radiography and MRI.

*Plain X-ray*: The SIJs of all patients and controls were evaluated in a blinded manner by a rheumatologist [SIJs (anteroposterior view)].

---

Grading of radiographic sacroiliitis: [14]

Grade 0: normal

Grade 1: suspicious changes

Grade 2: minimal abnormality – small localized areas with erosion or sclerosis, without alteration in the joint width

Grade 3: unequivocal abnormality – moderate or advanced sacroiliitis with one or more of erosions, evidence of sclerosis, widening, narrowing, or partial ankylosis

Grade 4: severe abnormality – total ankylosis

---

**MRI on sacroiliac joints:** The SIJs of all patients and controls were evaluated in a blinded manner by a radiologist. MRI was carried out using a 0.2-T GE machine with a spine phased-array coil. Two sequences were applied to patients: the coronal short tau inversion recovery (STIR) sequence and the axial T<sub>1</sub>-weighted sequence. Definition of sacroiliitis by MRI for application in the new ASAS classification criteria is as follows [10]:

---

Types of findings required for the definition of sacroiliitis by MRI:

Active inflammatory lesions of the SIJs (reflecting active sacroiliitis) are required for the definition of 'sacroiliitis on MRI' as one of The two imaging items in the ASAS classification criteria for axial SPA

Bone marrow edema (BME) on STIR or osteitis on T<sub>1</sub> post-gadolinium highly suggestive of SPA must be clearly present and located in the typical anatomical areas (subchondral or periarticular bone marrow)

The sole presence of other active inflammatory lesions such as synovitis, enthesitis, or capsulitis without concomitant BME/osteitis is not sufficient for the definition of sacroiliitis on MRI

Structural lesions such as fat deposition, sclerosis, erosions, or bony ankylosis are likely to reflect previous inflammation. At this time, however, the consensus group believed that the sole presence of structural lesions without concomitant BME/osteitis does not suffice for the fulfillment of sacroiliitis on MRI in the ASAS classification criteria for axial SPA

Amount of signal required:

If there is only one signal (lesion) per MRI slice suggesting active inflammation, the lesion should be present on at least two consecutive slices. If there is more than one signal (lesion) on a single slice, one slice may be sufficient

---

### Statistical analysis

Analysis of our data was carried out by a personal computer using the statistical package for the social sciences (version 16; SPSS Inc., Chicago, Illinois, USA) as follows: descriptive statistics: quantitative variables were described as mean, SD, and range and qualitative variables were described as number and percentage. Group comparisons were carried out using the  $\chi^2$  test, which was used to compare qualitative variables. Student's *t*-test was used to compare two independent groups in terms of quantitative variables. Correlation: Pearson's correlation coefficients (*r*) were calculated for the detection of parametric correlations, whereas Spearman's correlation coefficients (*r*) were calculated for the detection of nonparametric correlations between variables in one group. *P* value less than 0.05 was considered significant; *P* value less than 0.01 was considered highly significant.

---

### Results

Our study included two groups: groups I and II.

Group I included 20 healthy volunteers (10 men and 10 women) were included in the control group. Their age ranged from 18 to 37 years (mean 26.8 ± 6.2 years).

Group II included 60 SPAs patients recruited from the Rheumatology Outpatient Clinic in Al-Minia University Hospital, 36 (60%) men and 24 (40%) women; their age ranged between 18 and 39 years (mean 25.2 ± 5.2 years) and their disease duration ranged from 5 to 22 months (mean 9.62 ± 3.72 months). Thirty-eight (63.3%) patients had axial SPA and 22 (36.7%) patients had peripheral SPA. AS was diagnosed in 22 (36.6%) patients, followed by USPA in 12 (20%) patients, reactive arthritis in 10 (16.7%) patients, psoriatic arthropathy in 10 (16.7%) patients, and enteropathic arthropathy in six (10%) patients (Table 1). SPAs patients were subdivided into two groups: group IIA: SPAs with sacroiliitis and group IIB: SPAs without sacroiliitis (according to MRI results).

No statistically significant difference was found between the patients and the controls in age and sex. Laboratory and radiological findings in both groups also showed no statistically significant difference in erythrocyte sedimentation rate, CRP positivity, and CRP titer. However, there was a statistically significant difference between our two groups in HLA-B27 (*P* < 0.001) and there was a highly statistically significant difference in radiological findings of sacroiliitis (*P* < 0.001); the control group did not have sacroiliitis and were not positive for HLA-B27.

### Demographic data and primary complaint in patient subgroups

(1) Group IIA included 40 (66.7%) spondyloarthropathic patients with sacroiliitis, 28 (70%) men and 12 (30%) women. Their age ranged from 18 to 39 years (mean 26.9 ± 4.6 years), and their disease duration ranged from 4 to 22 months

**Table 1 Demographic data and the characteristics of patients and controls**

Demographic data	Patients	Controls
Age (mean ± SD) (years)	25.2 ± 5.2	26.8 ± 6.2
Sex [N (%)]		
Male	36 (60)	10 (50)
Female	24 (40)	10 (50)
Disease duration (mean ± SD) (months)	9.62 ± 3.72	–
Types of patients [N (%)]		
Axial SPAs	38 (63.3)	–
Peripheral SPAs	22 (36.7)	
Classification of patients [N (%)]		
Ankylosing spondylitis	22 (36.6)	–
Psoriasis	10 (16.7)	
Reiter's disease	10 (16.7)	
Enteropathic arthropathy	6 (10)	
USPAs	12 (20)	

SPA, spondyloarthropathy; USPA, undifferentiated spondyloarthropathy.



(mean  $11 \pm 4.89$  months). Thirty-eight (95%) patients presented primarily with inflammatory back pain and two (5%) patients presented with enthesitis. Thirty-six (90%) patients had axial SPA and four (10%) patients had peripheral SPAs (Figs. 1–3).

- (2) Group IIB included 20 (33.3%) patients without sacroiliitis. There were 10 (50%) men and 10 (50%) women; their age ranged from 20 to 35 years (mean  $24.5 \pm 3.7$  years), and their disease duration ranged from 4 to 8 months (mean  $4.82 \pm 1.25$  months). Fourteen (70%) patients presented primarily with enthesitis and six (30%) patients presented with arthritis. Two patients had axial SPAs and 18 patients had peripheral SPAs.

No statistically significant difference was found between patient subgroups in age and sex, whereas we found a statistically high significant difference in disease duration ( $P < 0.001$ ) and primary complaint ( $P < 0.001$ ) (Table 2).

The different manifestations and clinical examinations in spondyloarthritis patients are summarized in Tables 3 and 4. We found a highly statistically significant difference between both subgroups in inflammatory back pain ( $P < 0.001$ ), NSAIDs efficacy ( $P < 0.001$ ), and enthesitis ( $P < 0.004$ ). Also, a statistically significant difference was found between the subgroups in swollen joint count ( $P < 0.01$ ), tender joint count ( $P < 0.02$ ), and clinical sacroiliitis ( $P < 0.006$ ), whereas no statistically significant difference was found between the subgroups in other variables.

On comparing the activity indices in patients subgroups, we found a highly statistically significant difference between SPA patients subgroups in BASMI ( $P < 0.001$ ) (Table 5).

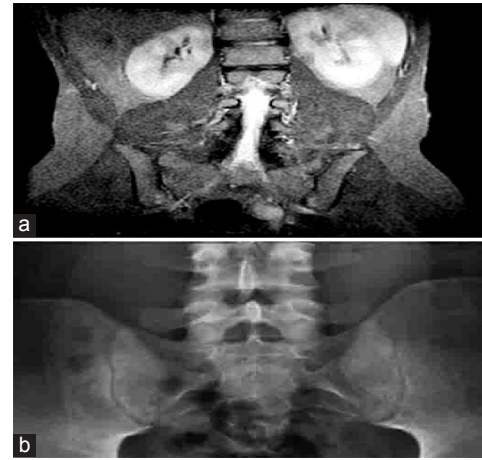
Laboratory and radiological findings in the patient subgroups are summarized in Table 6; there was a highly statistically significant relationship between patients with positive sacroiliitis and the positivity of HLA-B27. There was no statistically significant difference in other laboratory variables. All patients with radiological sacroiliitis showed sacroiliitis by MRI.

Table 7 shows no significant correlation between the MASES and HLA-B27-positive patients, and active sacroiliitis by MRI in SPA patients.

#### Comparison of sacroiliitis shown by magnetic resonance imaging and plain radiography

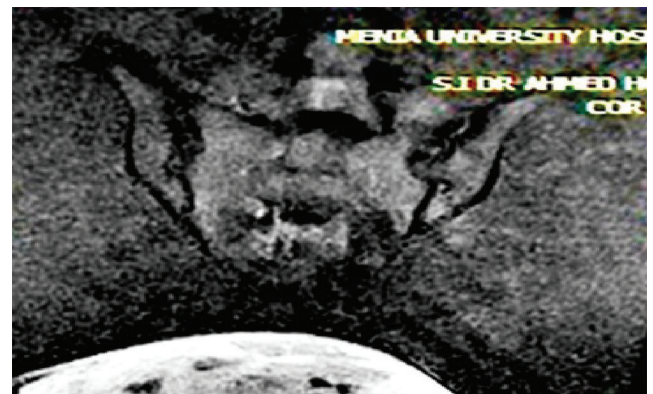
Sacroiliitis was detected in 40 patients (30 bilateral, 10 unilateral) by MRI and in 12 patients (eight bilateral,

Figure 1



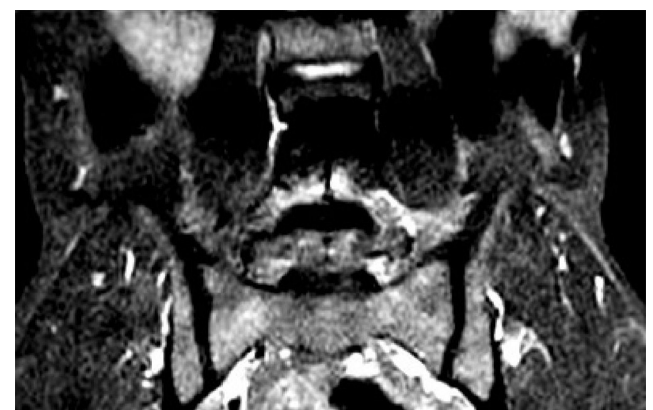(a) MRI sacroiliac joint (coronal short tau inversion recovery) in a 22-year-old axial spondyloarthropathy man showing bone marrow edema (arrows) bilaterally. (b) Radiograph of sacroiliac joints with sharp joint margins, no sclerosis, or erosions in the same patient.

Figure 2



MRI sacroiliac joint (coronal short tau inversion recovery sequence) in a 26-year-old axial spondyloarthropathy woman showing bone marrow edema.

Figure 3



MRI sacroiliac joint (coronal short tau inversion recovery sequence) in a 25-year-old axial spondyloarthropathy man showing bone marrow edema (arrows) bilaterally.

**Table 2 Comparison between demographic data and primary complaint in spondyloarthropathy subgroups**

Demographic data and primary complain	Group IIA (SPA with sacroiliitis) (N = 40)	Group IIB (SPA without sacroiliitis) (N = 20)	$\chi^2/t$	P value
Age (years)				
Range	18–39	20–35	0.942	0.3
Mean $\pm$ SD	25.9 $\pm$ 4.6	24.5 $\pm$ 3.7		
Disease duration (months)				
Range	4–22	4–8	3.992	0.001**
Mean $\pm$ SD	11 $\pm$ 4.89	4.82 $\pm$ 1.25		
Sex [N (%)]				
Male	28 (70)	10 (50)	1.531	0.5
Female	12 (30)	10 (50)		
Primary complaint [N (%)]				
Inflammatory LBP	38 (95)	0 (0)	26.232	0.001**
Arthritis	0 (0)	6 (30)		0.001**
Enthesitis	2 (5)	14 (70)		0.001**

LBP, low back pain; SPA, spondyloarthropathy; \*\* $P < 0.01$ , highly significant.

**Table 3 Comparison between different manifestations in patient subgroups**

Different manifestation of patient subgroup	N (%)		$\chi^2$	P value
	Group IIA (n = 40)	Group IIB (n = 20)		
Inflammatory LBP	38 (95)	0 (0)	30	0.001**
Enthesitis	20 (50)	20 (100)	8.68	0.004**
Arthritis	9 (22.5)	11 (55)	3.51	0.07
Psoriasis	2 (5)	8 (40)	1.407	0.3
IBD	4 (10)	2 (10)	2.01	0.3
CD	3 (7.5)	1 (5)	0.164	0.6
UC	1 (2.5)	1 (5)	1.787	0.3
Preceding infection	6 (15)	4 (20)	1.407	0.3
UTI	5 (12.5)	3 (15)	0.353	0.4
Genital infection	1 (2.5)	1 (5)	1.787	0.3
Buttock pain	4 (10)	0 (0)	1.24	0.3
Family history	10 (25)	0 (0)	3.47	0.08
NSAIDs efficacy	36 (90)	4 (20)	18.75	0.001**

CD, Crohn's disease; IBD, inflammatory bowel disease; LBP, low back pain; UC, ulcerative colitis; UTI, urinary tract infection; \*\* $P < 0.001$ , highly significant.

four unilateral) in plain radiography. Thus, 20 affected sacroiliac joint (SIJ) were detected by plain radiography and 70 by MRI. MRI detected sacroiliitis in 50 joints, which were normally detected by plain radiography.

Erosions were observed in two out of 20 joints by plain radiography and 20 out of 70 joints by MRI. Observation of joint cartilage in high signal intensity in  $T_1^*$  FLASH 2D facilitated the evaluation of erosion as bone defects are related to the surface of the joint. MRI was positive in 18 joints that were normally detected by plain radiography.

Sclerosis was observed in 36 out of 70 joints by MRI and 12 out of 20 joints by plain radiography. Sclerosis was mostly found in the cartilaginous portion of the joints.

Alterations in joint width: changes in joint width, either narrowing or widening, were observed in 22 out of 70 joints by MRI and in eight out of 20 joints by plain radiography. The changes were mainly observed in the cartilaginous portion of the joints.

BME was detected in 48 (68.5%) joints with sacroiliitis by MRI (Figs. 1–4). STIR could demonstrate all of the joints with BME. BME predominantly occurred in the cartilaginous portion and at the iliac side of the joints. Enhancement of bone was observed in 46 (65.7%) joints. Enhancement was observed in both ligamentous and cartilaginous portions of the joints, but most often in the latter and on the iliac sides.

BME and contrast enhancement occurred simultaneously in 46 (65.6%) and were absent in 24 (34.3%) of the joints with sacroiliitis. BME was observed in two (2.8%) of the joints with sacroiliitis without signs of enhancement.

Enhancement in the joint space was observed in 28 (40%) of the joints with sacroiliitis by MRI. It occurred in both joint portions, but more frequently in the cartilaginous than in the ligamentous portion of the joints. Also, all these 28 SIJ had an abnormal high signal in the joint space on STIR.

BME and enhancement in the joint space were observed simultaneously in 18 (25.7%) joints. In 30 (42.9%) of the joints, BME was observed without enhancement in the joint space. In 10 (14.3%) of the joints, enhancement in the joint space was present without BME. Considering the fact that enhancement in the joint space and BME are findings compatible with active inflammation, inflammatory changes in 58 joints might be significant for active sacroiliitis.

**Table 4 Comparison between clinical examinations in patient subgroups**

Clinical examination	N (%)		$\chi^2/t$	P value
	Group IIA (N = 40)	Group IIB (N = 20)		
Arthritis	9 (22.5)	11 (55)	3.517	0.07
Hip arthritis	2 (5)	2 (10)	0.164	0.6
Knee arthritis	6 (15)	8 (40)	1.648	0.2
Ankle arthritis	5 (12.5)	8 (40)	2.907	0.1
Wrist arthritis	0 (0)	2 (10)	1.787	0.3
Small hand joints arthritis	0 (0)	4 (20)	0.73	0.8
SJC (mean $\pm$ SD)	0.37 $\pm$ 0.83	1.64 $\pm$ 1.69	-2.76	0.01*
TJC (mean $\pm$ SD)	0.47 $\pm$ 1.073	1.82 $\pm$ 1.94	-2.45	0.02*
Psoriatic rash	2 (5.3)	6 (27.3)	2.921	0.1
Psoriatic nail	6 (15)	2 (10)	0.353	0.4
Dactylitis	1 (2.5)	3 (15)	3.701	0.1
Uveitis	4 (10)	0 (0)	1.241	0.3
Clinical sacroiliitis	18 (45)	0 (0)	2.81	0.006**

SJC, swelling joint count; TJC, total joint count; \* $P < 0.05$ , significant; \*\* $P < 0.001$ , highly significant.

**Table 5 Comparison of different indices of spondyloarthropathy between patient subgroups**

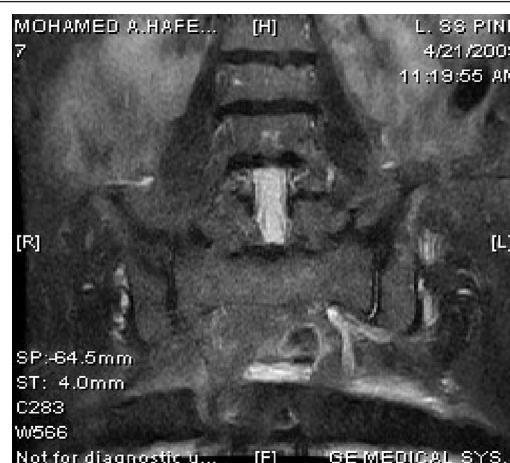Indices of spondyloarthropathy	Mean $\pm$ SD		t	P value
	Group IIA	Group IIB		
BASDAI	2.1 $\pm$ 0.8	1.6 $\pm$ 0.5	1.79	0.4
BASMI	0.9 $\pm$ 0.8	0.08 $\pm$ 0.1	0.28	0.001**
BASFI	2.7 $\pm$ 0.4	2.6 $\pm$ 0.4	3.77	0.7
Chest expansion	6.4 $\pm$ 0.3	6.4 $\pm$ 0.2	-1.34	0.2
MASES	0.9 $\pm$ 1.5	1.4 $\pm$ 1.5	1.4	0.3

BASDAI, Bath Ankylosing Spondylitis Disease Activity Index; BASFI, Bath Ankylosing Spondylitis Functional Index; BASMI, Bath Ankylosing Spondylitis Metrology Index; MASES, Maastricht Ankylosing Spondylitis Enthesitis Score; \*\* $P < 0.01$ , highly significant.

## Discussion

The diagnosis of sacroiliitis is important in planning a treatment of the disease and in establishing a follow-up protocol for patients with SPA. This study showed that MRI had the maximum sensitivity (66.7%) for detecting sacroiliitis. Their utility was most apparent in patients with disease duration less than 2 years. Plain radiographs showed the least sensitivity (20%) in detecting sacroiliitis. MRI was also very useful in the subgroup of patients with USPA where the radiographs were universally negative. This was in agreement with Shanmuganandan and colleagues [15,16], who reported that MRI had the maximum sensitivity (78%) for detecting sacroiliitis, followed closely by bone scan (73%). Their utility was most apparent in patients with disease duration less than 2 years. They were also very useful in the subgroup of patients with USPA.

In our study, we used MRI in the evaluation of SIJs. MRI has excellent soft-tissue contrast resolution, enabling a clear distinction of the two portions of the SIJ on the basis of a well-delineated differentiation between fatty tissue in the ligamentous portion and

**Figure 4**

MRI sacroiliac joint (coronal short tau inversion recovery sequence) showing effusion of the left sacroiliac joint.

cartilage in the cartilaginous portion. This was in agreement with other studies [15,17,18].

In our study, MRI visualizes early active inflammatory changes in the form of BME and contrast enhancement, enabling the diagnosis of sacroiliitis by MRI before definite joint destruction is detectable by radiography. This was in agreement with previous authors [15,19–22]. MRI is documented in the literature, as in our study, as a unique imaging method for the detection of early and active sacroiliitis [15,23]. Advances in superficial coil technology, invention of new sequences, and fast visualization methods are the factors increasing the sensitivity of MRI in the detection of early sacroiliitis [15,24].

Our findings support the concept that MRI is very useful for the early diagnosis of SPA. It has been reported that the combination of MRI features typical



**Table 6 Comparison between laboratory and radiological findings in spondyloarthropathies subgroups**

Laboratory and radiological finding	Group IIA (n = 40)	Group IIB (n = 20)	$\chi^2/t$	P
ESR (1st hour) (mean $\pm$ SD)	25.7 $\pm$ 11.5	27.6 $\pm$ 13.01	-0.896	0.3
CRP positivity [N (%)]	18 (45)	10 (50)	0.433	0.3
CRP titer (mean $\pm$ SD)	12.89 $\pm$ 19.4	18.64 $\pm$ 21.9	-0.782	0.4
HLA-B27 <sup>a</sup> [N (%)]	30 (75)	2 (10)	11.32	0.001**
Radiological sacroiliitis <sup>b</sup> [N (%)]	12 (30)	0 (0)	1.29	0.2

CRP, C-reactive protein; ESR, erythrocyte sedimentation rate; HLA-B27, human leukocyte antigen-B27; <sup>a</sup>Number of positive patients (%);

<sup>b</sup>Suspicious radiological sacroiliitis: radiological sacroiliitis that did not fulfill the modified New York criteria for ankylosing spondylitis, positive active sacroiliitis by MRI: bone marrow edema at the coronal short tau inversion recovery sequence; \*\* $P < 0.01$ , highly significant.

**Table 7 Correlation between the Maastricht Ankylosing Spondylitis Enthesitis Score with HLA-B27 and sacroiliitis by MRI in spondyloarthropathy patients**

HLA-B27 and sacroiliitis by MRI	MASES	
	R	P value
HLA-B27	0.217	0.2
Sacroiliitis by MRI	0.11	0.5

HLA-B27, human leukocyte antigen-B27, MASES, maastricht ankylosing spondylitis enthesitis score.

of sacroiliitis with IBP and HLA-B27 positivity has a higher probability of being diagnosed as axial SPA in patients with well-established symptoms and this was in agreement with previous studies [25,26].

Some previous studies have examined the utility of MRI in early SPA. One longitudinal study investigated MRI, computed tomography, and radiographic changes in the SIJs over 1 year in 34 patients with early inflammatory back pain (IBP) [27]. No correlation was found between MRI scores and radiographic changes at follow-up. Oostveen *et al.* [21] investigated 25 HLA-B27-positive patients to assess the diagnostic value of MRI in the detection of early sacroiliitis. These patients were followed up for 3 years; nine of 14 patients showed structural changes in sacroiliitis by MRI and six out of nine patients showed inflammatory changes on MRI at baseline and subsequently developed AS. Oostveen *et al.* [21] emphasized the positive predictive value of structural changes observed on MRI for future radiographically evident AS rather than the predictive role of inflammatory changes.

In the present study, we focused on grading acute inflammatory osteitis in the form of BME rather than structural changes since Van der Heijde *et al.* [28] concluded that scoring inflammation is more important than scoring structural changes on MRI. Also, in the present study of very early disease, we noted that structural changes were uncommon.

In our study, the advantages of MRI compared with plain radiography in evaluating sacroiliitis include detection of BME and detection of enhancement in the joint space, which was in agreement with another study [15]. The capability of MRI to distinguish between acute and chronic changes and estimate

the degree of disease activity can be beneficial in monitoring the effect of pharmacological treatment; the same result was reported by other authors [15,29].

## Conclusion

MRI is the preferred modality in patients with early SPA and in those with USPA as it is now clear that early diagnosis can enable early treatment, which has been shown to yield significant symptomatic and radiological improvements. MRI can distinguish between acute and chronic changes. This capability would be beneficial for classifying different forms of SPAs and monitoring disease progression before, during, and after any drug treatment. MRI should therefore be used whenever possible to evaluate sacroiliitis. HLA-B27 positivity is a highly useful predictor of early sacroiliitis.

## Acknowledgements

Thanks are due to all members of the rheumatology, radiology, and clinical pathology departments for their cooperation.

## Financial support and sponsorship

Nil.

## Conflicts of interest

There are no conflicts of interest.

## References

- Zochling J, Brandt J, Braun J. The current concept of spondyloarthritis with special emphasis on undifferentiated spondyloarthritis. *Rheumatology (Oxford)* 2005; **44**:1483–1491.
- Baraliakos X, Braun J. Spondyloarthritis. *Best Pract Res Clin Rheumatol* 2011; **25**:825–842.
- Zochling J, Smith EUR. Spondyloarthropathy. *Best Pract Res Clin Rheumatol* 2010; **24**:747–756.
- Reveille J. HLA-B27 and the seronegative spondyloarthropathy. *Am J Med Sci* 1998; **316**:239–249.
- Mody GM, Parke FA, Reveille JD. Articular manifestations of human immunodeficiency virus infection. *Best Pract Res Clin Rheumatol* 2003; **17**:265–287.
- Hülsmeier M, Fiorillo MT, Bettosini F, Sorrentino R, Saenger W, Ziegler A, Uchanska-Ziegler B. Dual, HLA-B27 subtype-dependent conformation

- of a self-peptide. *J Exp Med* 2004; **199**:271–281.
- 7 Atagunduz P, Appel H, Kuon W, Wu P, Thiel A, Kloetzel PM, Sieper J. HLA-B27-restricted CD8+ T cell response to cartilage-derived self peptides in ankylosing spondylitis. *Arthritis Rheum* 2005; **52**:892–901.
  - 8] Ehrenfeld M. Spondyloarthropathies. *Best Pract Res Clin Rheumatol* 2012; **26**:135–145.
  - 9 Dougados M, van der Linden S, Juhlin R, Huitfeldt B, Amor B, Calin A, *et al.* The European Spondylarthropathy Study Group preliminary criteria for the classification of spondylarthropathy. *Arthritis Rheum* 1991; **34**:1218–1227.
  - 10 Rudwaleit M, van der Heijde D, Landewé R, Listing J, Akkoc N, Brandt J, *et al.* The development of Assessment of SpondyloArthritis international Society classification criteria for axial spondyloarthritis (part II): validation and final selection. *Ann Rheum Dis* 2009; **68**:777–783.
  - 11 Rudwaleit M, van der Heijde D, Landewé R, Akkoc N, Brandt J, Chou CT, *et al.* The Assessment of SpondyloArthritis International Society classification criteria for peripheral spondyloarthritis and for spondyloarthritis in general. *Ann Rheum Dis* 2011; **70**:25–31.
  - 12 Sieper J, Rudwaleit M, Baraliakos X, Brandt J, Braun J, Burgos-Vargas R, *et al.* The Assessment of SpondyloArthritis international Society (ASAS) handbook: a guide to assess spondyloarthritis. *Ann Rheum Dis* 2009; **68** (Suppl 2):ii1–ii44.
  - 13 Seipp MT, Erali M, Wies RL, Wittwer C. HLA-B27 typing: evaluation of an allele-specific PCR melting assay and two flow cytometric antigen assays. *Cytometry B Clin Cytom* 2005; **63**:10–15.
  - 14 Van der Linden S, Valkenburg HA, Cats A. Evaluation of diagnostic criteria for ankylosing spondylitis. A proposal for modification of the New York criteria. *Arthritis Rheum* 1984; **27**:361–368.
  - 15 Çalışır C, Korkmaz C, Kaya T. Comparison of MRI and CT in the diagnosis of early sacroiliitis. *Med J Kocatepe* 2006; **6**: 49–56.
  - 16 Shanmuganandan K, Shankar S, Raphael J, Grover R, Sridhar CM, Sreeram MN. A comparative evaluation of MRI, radionuclide bone scan and plain radiographs in Indian patients with spondyloarthropathy. *Indian J Rheumatol* 2006; **1**:53–59.
  - 17 Oostveen JC, van de Laar MA. Magnetic resonance imaging in rheumatic disorders of the spine and sacroiliac joints. *Semin Arthritis Rheum* 2000; **30**:52–69.
  - 18 Puhakka KB, Melsen F, Jurik AG, Boel LW, Vesterby A, Egund N. MR imaging of the normal sacroiliac joint with correlation to histology. *Skeletal Radiol* 2004; **33**:15–28.
  - 19 Blum U, Buitrago Tellez C, Mundinger A, Krause T, Laubenberger J, Vaith P, *et al.* Magnetic resonance imaging (MRI) for detection of active sacroiliitis: a prospective study comparing conventional radiography, scintigraphy and contrast enhanced MRI. *J Rheumatol* 1996; **23**:2107–2115.
  - 20 Braun J, Sieper J. The sacroiliac joint in the spondyloarthropathies. *Curr Opin Rheumatol* 1996; **8**:275–287.
  - 21 Oostveen J, Prevo R, den Boer J, van de Laar M. Early detection of sacroiliitis on magnetic resonance imaging and subsequent development of sacroiliitis on plan radiography. A prospective, longitudinal study. *J Rheumatol* 1999; **26**:1953–1958.
  - 22 Bollow M, Braun J, Biedermann T, Mutze S, Paris S, Schauer-Petrowskaja C, *et al.* Use of contrast-enhanced MR imaging to detect sacroiliitis in children. *Skeletal Radiol* 1998; **27**:606–616.
  - 23 Wittram C, Whitehouse GH, Williams JW, Bucknall RC. A comparison of MR and CT in suspected sacroiliitis. *J Comput Assist Tomogr* 1996; **20**:68–72.
  - 24 Braun J, Bollow M, Eggens U, König H, Distler A, Sieper J. Use of dynamic magnetic resonance imaging with fast imaging in the detection of early and advanced sacroiliitis in spondylarthropathy patients. *Arthritis Rheum* 1994; **37**:1039–1045.
  - 25 Bennett AN, McGonagle D, O'Connor P, Hensor EM, Sivera F, Coates LC, *et al.* Severity of baseline magnetic resonance imaging-evident sacroiliitis and HLA-B27 status in early inflammatory back pain predict radiographically evident ankylosing spondylitis at eight years. *Arthritis Rheum* 2008; **58**:3413–3418.
  - 26 Rudwaleit M, van der Heijde D, Khan MA, Braun J, Sieper J. How to diagnose axial spondyloarthritis early. *Ann Rheum Dis* 2004; **63**:535–543.
  - 27 Puhakka KB, Jurik AG, Schiøttz-Christensen B, Hansen GV, Egund N, Christiansen JV, Stengaard-Pedersen K. MRI abnormalities of sacroiliac joints in early spondyloarthropathy: a 1-year follow-up study. *Scand J Rheumatol* 2004; **33**:332–338.
  - 28 Van der Heijde DM, Landewé RB, Hermann KG, Jurik AG, Maksymowych WP, Rudwaleit M, *et al.* Application of the OMERACT filter to scoring methods for magnetic resonance imaging of the sacroiliac joints and the spine. Recommendations for a research agenda at OMERACT 7. *J Rheumatol* 2005; **32**:2042–2047.
  - 29 Antoni C, Dechant C, Ogilvie A, Kalden ND, Kalden JR, Manger B. Successful treatment of psoriatic arthritis with infliximab in a MRI controlled study. *J Rheumatol* 2000; **27**:24.