

# Predictive factors for progression of adolescent idiopathic scoliosis: a 1-year study

Enas A. Elattar, Nayera Z. Saber, Dina A. Farrag

Department of Physical Medicine,  
Rheumatology and Rehabilitation, Faculty of  
Medicine, Ain Shams University, Cairo, Egypt

Correspondence to Enas Abdallah Elattar,  
MD, Department of Physical Medicine,  
Rheumatology and Rehabilitation, Faculty of  
Medicine, Ain Shams University, El Shorouk  
City, Cairo 11957, Egypt  
Tel: +20 111 312 3806; fax: +20 226 304 282;  
e-mail: enasattar2@yahoo.com

**Received** 07 January 2015

**Accepted** 20 April 2015

**Egyptian Rheumatology & Rehabilitation**  
2015, 42:111–119

## Background and objective

The cause of scoliosis remains unknown in 80–85% of adolescent patients. Treatment of adolescent idiopathic scoliosis (AIS) remains a complex challenge.

## Aim

The goal of this study was to evaluate the predictive value of different factors [age, initial Risser's score and initial Cobb's angle, surface electromyography (SEMG), activity of both paraspinal muscles at the apex of the curve] in the progression of AIS.

## Patients and methods

This study included 30 patients with AIS. Full history taking and spinal and neurological examinations were carried out. Initial Cobb's angle and Risser's staging were determined, together with SEMG of paraspinal muscles at the curve's apex. Reassessment of Cobb's angle and Risser's score was done 1 year later.

## Statistical analysis

Analysis of data was carried out with an IBM computer using statistical program for social science (version 18) software and services.

Quantitative data were presented as mean, SD, minimum and maximum values, and range. Qualitative data were presented as number and percentage, analyzed with the  $\chi^2$ -test. Analytic statistics were calculated using Student's *t*-test to compare two independent means. A receiver-operating character curve was constructed using Medcalc program 3.5.

## Results

Twenty-six girls and four boys with dorsal and dorsolumbar scoliosis were included in this study. There was significant increase in Cobb's angle and Risser's score. Age, Risser's score, and SEMG results on the convex side were significantly correlated with progression of the curve. Cobb's angle was the most sensitive predictor, followed by SEMG, whereas age, initial Risser's score, and SEMG had the highest specificity as predictors.

## Conclusion

Cobb's angle, Risser's score, and SEMG are specific, sensitive, and positive predictors for progression of AIS.

## Keywords:

adolescent idiopathic scoliosis, Cobb's angle, Risser's score, surface electromyography

Egypt Rheumatol Rehabil 42:111–119

© 2015 Egyptian Society for Rheumatology and Rehabilitation  
1110-161X

## Introduction

Scoliosis is present in 3–5% of children in the adolescent age group, with a higher incidence in girls. The cause of scoliosis in this age group is unknown in the majority of cases (80–85%), and it is therefore called adolescent idiopathic scoliosis (AIS). Successful treatment of AIS remains a complex challenge for the orthopedic surgeon. Generally, treatment is conservative (observational or brace therapy) until curves progress to more than 45–50° on the Cobb angle. Scoliotic curves larger than 50° are usually treated surgically, together with braces. The proper timing of treatment depends on the curve's progression. However, exact prediction of curve progression in patients with AIS is still difficult as the prognosis of the deformity is different in each individual [1].

A documented relationship between growth of the patient and increase in spinal deformity has been shown, where the rapid increase in spinal height at pubertal spurt causes an increase in the spinal curvature [1,2]. Maturity is multidimensional and has various components, including chronological age, skeletal age as per Risser's sign, status of the triradiate cartilage, Tanner stage of sexual maturation, age at thelarche and menarche, and several length dimensions [1]. The Risser sign (ossification of the iliac apophysis) continues to be an

This is an open access article distributed under the terms of the Creative Commons Attribution-NonCommercial-ShareAlike 3.0 License, which allows others to remix, tweak, and build upon the work non-commercially, as long as the author is credited and the new creations are licensed under the identical terms.

accepted prognostic sign in the evaluation of growth of patients with idiopathic scoliosis. However, there is considerable controversy [3]. The disadvantage of using the Risser sign is the wide distribution and the fact that it typically appears after peak growth velocity of height. Risser stage 1 occurs after growth spurt in 85% of patients, and thus its predictive value is very low [4]. Sanders *et al.* [5,6] found the status of the triradiate cartilage to be more predictive for the timing of the peak growth velocity of total body height. Once the patient has closed triradiate cartilages, he or she is very likely past the pubertal growth spurt, although it is only predictive [7].

Researchers have tried to find different ways of predicting curve progression in AIS, using pubertal growth spurt, Risser's sign, and modified Risser's sign. Many authors [8,9] have found a relationship between curve progression and altered electromyography of paraspinal muscle activity of both convex and concave sides of the curve. Independently of the nature of origin of the initial abnormal spine curvature it causes nonsymmetrical loading of vertebrae (postural imbalance) and nonsymmetrical muscle activities [10]. Some of the spine muscles are shortened, with greater tension; some of them are elongated with decreased force capabilities. This imbalance influences reaction forces between the vertebrae and further damages their anatomical structure [11].

Clinical electromyography (EMG) is often used for preoperative and postoperative assessment of neuromuscular activation and muscle coordination. Moreover, many authors have stated that suitable processed SEMGs of spinal muscles can be used as a preoperative noninvasive tool or as a tool for estimation of usefulness of different treatment strategies of scoliotic patients [12].

---

### Aim of the work

The goal of this study was to determine the predictive value of different factors such as age, initial Risser's score (iRisser's score), and initial Cobb's angle and surface electromyography (SEMG) activity of paraspinal muscles on the concave and convex side of the curve in the progression of AIS. Furthermore, different parameters are evaluated for their correlation with curve progression in the individual scoliosis patient.

---

### Patients and methods

The study was a longitudinal prospective cohort study. It included 30 patients with AIS presenting to

Physical Medicine, Rheumatology and Rehabilitation outpatient clinic, or referred from orthopedic clinics.

### Inclusion criteria

Adolescent patients aged 10–18 years with a dorsal scoliotic curve (Cobb's angle 10–25°) presenting at our hospital or referred for conservative management were eligible for inclusion in the study.

### Exclusion criteria

- (1) True leg-length discrepancy.
- (2) Previous spinal surgery.
- (3) Bone tumor, trauma, neurological deficit.
- (4) Associated pathologies of lower limbs that may interfere with the global posture, such as foot, knee, and hip deformities.
- (5) Previous brace use.
- (6) Scoliosis with Cobb's angle greater than 25°.

Parents of all the patients who met the inclusion criteria were asked to give consent so that their children could participate in the study.

---

### Methods

All patients were subjected to the following.

#### Full history taking

- (1) Patient or parents were asked about the presenting complaint with special stress on pain, deformity, and shoulder or leg discrepancy.
- (2) History suggestive of systemic illness or disability, musculoskeletal, neurological, cardiovascular or renal problems.
- (3) History of similar condition in the family.
- (4) Past history of severe illness, medications, surgeries, injuries, or bracing.

#### Complete clinical and neurological examination

- (1) Spinal examination for spinal deformity, kyphosis, flat back, hyperlordosis, or scoliosis
- (2) Evaluation of tenderness of the spine, alignment, muscle spasm, discrepancy of shoulders, and discrepancy in lower limb length.
- (3) Inspection of skin for the presence of birth marks or café au lait patches, scars, gibbus deformity, and sinuses.
- (4) Adam's forward bending test.
- (5) Neurological examination to determine muscle state, power, tendon reflexes, sensation, coordination, and proprioception.

- (6) Posture, balance, and gait examination.
- (7) Classification of scoliosis according to the Lenke classification [13].

### Instrumentation and measurements

#### Radiographs

As a clinically important increase in curve severity exists between morning and evening [14], all radiographic examinations were taken in the morning using a standardized radiographic protocol.

- (1) Full-length anteroposterior and lateral radiograph of the spine and the iliac crest were taken for each patient [15].
- (2) The angle of the scoliotic curve was measured using Cobb's method. Cobb's angle is the angle determined by the intersection between the superior surface of the superior end vertebra and the inferior surface of the inferior end vertebra [16]. Cobb's angle was measured by the three investigators and an average was calculated.
- (3) Degree of skeletal maturity (Risser's staging) was determined by the three investigators and if differences existed the two closest staging results were adopted.

In Risser's staging, the US Risser's grading system was used [17]:

Stage 0, the apophysis of the iliac crest is not present.

Stage I: the apophysis covers 25% of the iliac crest.

Stage II, the apophysis covers 50% of the iliac crest.

Stage III, the apophysis covers 75% of the iliac crest.

Stage IV, the apophysis covers 100% of the iliac crest.

Stage V, adult pelvis.

- (4) SEMG: using a Schwarzer GmbH Topaz Germany 2006 apparatus (Natus Medical Incorporated, Planegg, Germany), SEMG was performed on the paraspinal muscles on either side of the curve to compare muscle activity on the convex and concave side of the main scoliotic curve at the level of the apex [8].

### Procedure

The skin at the electrode sites was abraded and cleaned with alcohol. Two pairs of bipolar SEMG electrodes were placed symmetrically along the superficial erector spinae muscles, 30 mm from the midline, and parallel to the spinous processes on either side of the scoliotic curve.

Active electrodes were located on either side of the apex of the convexity, whereas reference electrodes

were located 4 cm distal to the active electrodes.

Recording in the sitting position was carried out for 30 seconds with the patient sitting relaxed with his or her back supported.

Recording in the standing position was started from the commencement of standing until upright posture was achieved, for a duration of 30 s

The electrodes were connected to a two-channel physiologic recording device. Raw EMG signals are amplified, AD-converted, and stored at a sampling rate of 800 Hz in a computer for analysis. The EMG signals are full-wave rectified and low-pass filtered.

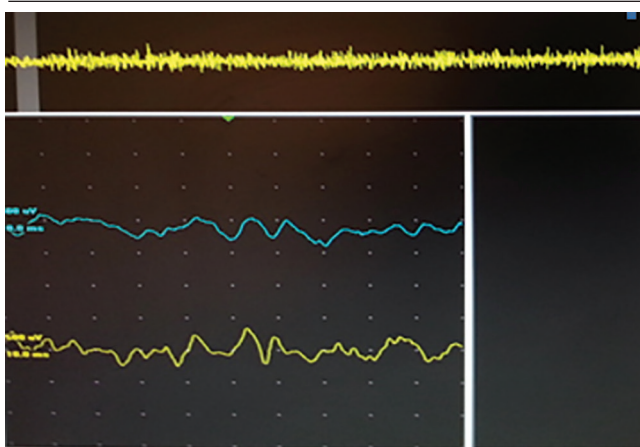
As we were using SEMG, testing of the resting activities and single motor unit parameters was difficult; in other studies we had analyzed the interference pattern (IP) [8]. Analysis of the IP was carried out by qualitative and quantitative methods. In the qualitative method, we reported on the fullness and completeness of the IP. In qualitative methods the recruitment was registered and we reported on AMP/TURN, TURN/SEC, and activity, which were the only selected parameters for measuring the fullness of IP; we reported on recruitment as an indicative factor of complete IP.

Figure 1 shows SEMG recording of erector spinae in patient no. 4.

### Rehabilitation program

Parents were reassured and educated about the deformity and about the study nature. Patients were observed through a routine outpatient rehabilitation program; no orthotic or surgical measures were taken as none of the curves exceeded 25°.

Figure 1



Two-channel surface electromyography of erector spinae of dorsal spine value.

### Exercise program

Patients underwent supervised exercise sessions in the outpatient clinic three times a week for 6 weeks every 3 months. They were advised to continue this 45-min exercise schedule at home in between clinical sessions.

Each patient received a handout with drawings showing how to perform the exercise.

- (1) Warming up exercise for 10 min, including breathing and stretching exercise.
- (2) Corrective exercise, including exercise to improve muscle balance and mobility, combined with stretching exercise for posture correction.

Cat camel exercise:

Stretching exercises for the hypomobile structures on the concave side of the curve and traction on the wall bar.

- (3) Exercise to improve spinal stability, static and dynamic strengthening of abdominal muscles, abdominal hollowing, bridging exercise, four-point arm, leg reach.
- (4) Functional strengthening exercise, including ball exercise for supine hip extension and stability ball back extension, isoabdominal prone and side-lying exercise, and lateral bending for spine.
- (5) Power crunch and oblique ball twist to improve coordination and restore function [18,19].

### Follow-up

After 1 year, patients were re-evaluated using the same methods, and predictors for curve progression were calculated.

### Statistical analysis

All data were collected, tabulated, and statistically analyzed.

Analysis of data was carried out with an IBM computer using statistical program for social science version 18 software and services (SPSS Inc. Released 2009. PASW Statistics for Windows, Version 18.0. Chicago).

Quantitative data were presented as mean, SD, minimum and maximum values, and range; qualitative data were presented as number and percentage, analyzed by the  $\chi^2$ -test.

Analytic statistics were calculated using the Student *t*-test to compare two independent means. *P* values less than 0.001 were considered highly significant (HS), whereas values less than 0.05 were considered significant (S).

A receiver-operating character (ROC) curve was constructed using Medcalc program 3.5 (MedCalc Software, Ostend, Belgium). The ROC analysis curve is a method to compare the results of various tests and to evaluate the diagnostic accuracy of a test for the same outcome by plotting the true-positive results (sensitivity) against the false-negative results (specificity).

Thus, it can evaluate the balance between sensitivity and specificity of a diagnostic test over a variety of cutoff points. An ROC analysis curve was constructed for variables age, initial Cobb's angle, iRisser's score, and initial EMG of concave and convex sides.

Relationships between parameters were analyzed using Pearson's correlation coefficients (*r*).

### Results

This study included 26 girls and four boys aged 9–17 years, with a mean age of  $13.567 \pm 2.344$  years who were diagnosed as AIS patients without any systemic illness, no lower limb discrepancy, and no evidence of neurological abnormality.

Back examination revealed 19 patients with dorsal pain and four patients with secondary lumbar curves.

The Adams bending test showed a dorsal hump in 20% of patients.

Nineteen girls (19/26, 73%) had reached menarche, whereas only one boy (1/4, 25%) had reached puberty.

Full-length A–P and lateral radiograph of the spine and the iliac crest revealed dorsal scoliosis (apex T8–T10) and absence of spinal rotation, with mean initial Cobb's angle of  $15.233 \pm 4.65$  for all patients, and with highly significant difference between girls and boys ( $t = 6.878$ ,  $P < 0.001$ ).

iRisser's staging score at the start of the study showed the following:

- (1) Fourteen patients (46.6%) in stage 0;
- (2) Three patients (10%) in stage 1;
- (3) Nine patients (30%) in stage 2; and
- (4) Four patients (13.3%) in stage 3.

Moreover, the initial Cobb's angle was not significantly correlated with patient age ( $r = -0.058$ ,  $P > 0.761$ ), nor with the iRisser's score ( $r = -0.125$ ,  $P > 0.509$ ).

SEMG recording in standing and sitting position on either side of the apex of the dorsal spinal deformity

(scoliotic curve) was calculated, as well as the mean muscle activity on the convex side ( $81.53 \pm 10.191$ ), which was higher than that recorded from the concave side ( $41.267 \pm 5.84$ ) with EMG ratio of  $1.97 \pm 1.74$ . On comparing muscle activity there was high statistically significant difference ( $P < 0.001$ ) between the two sides.

Follow-up of the patients during their rehabilitation program over the course of 1 year was satisfying without any complaints or complications. In this cohort, we studied the effect of many variants on curve progression, such as age, sex, skeletal maturity (Risser's score), and findings of the SEMG on the convex and concave side. All patients were re-evaluated at the end of the study period regarding curve progression evaluated with Cobb's angle (mean became  $19.200 \pm 5.095$ ), which revealed significant increase in Cobb's angle ( $t = -6.789$ ,  $P < 0.001$ ). This progression occurred in 16 patients (53.33%) (progressive group) of the 30, whereas the initial Cobb's angle did not change in 10 patients (33.3%) and decreased (improved on exercise rehabilitation program) in four patients (13.33%) (nonprogressive group).

For sex, there was no significant difference in curve progression between boys and girls ( $\chi^2 = 0.021$ ,  $P = 0.886$ ) (Table 1).

In contrast, there was significant difference between the progressive and nonprogressive group regarding age and SEMG on both sides of the curve (Table 2). Table 2 also highlights lower values of age and SEMG

activity on the concave side, compared with higher values of SEMG on the convex side of the progression group.

Skeletal maturity by Risser's staging score and results were compared with previous ones at the start of the study, which showed significant progress in skeletal maturity through an increase in Risser's score in 14 adolescents within the progressive group, in contrast to only two adolescent of the nonprogressive group (Table 3).

We used the ROC curve to analyze all of the measured parameters to determine the most predictive parameter in curve progression. The ROC curve demonstrated the sensitivity, specificity, positive and negative predictive values, and accuracy of each parameter at a certain cutoff level.

It was found that age, iRisser's staging, and SEMG of the convex side were the most specific factors for curve progression (100%), whereas Cobb's angle was

**Table 1 Comparison between boys and girls regarding curve progression**

Sex	Progression		
	Nonprogression	Progression	Total
Sex [N (%)]			
Female	12 (40.00)	14 (46.67)	26 (86.67)
Male	2 (6.67)	2 (6.67)	4 (13.33)
Total	14 (46.67)	16 (53.33)	30 (100.00)
$\chi^2$		0.021	
P-value		0.886	

**Table 2 Comparison between curve progression and nonprogression with respect to age and surface electromyography**

Variants	Progression			t-Test	Significance
	Nonprogression (mean $\pm$ SD)	Progression (mean $\pm$ SD)	t		
Age	16.222 $\pm$ 0.833	12.429 $\pm$ 1.777	6.079	0.000	HS
EMG convex	69.222 $\pm$ 5.019	86.810 $\pm$ 6.570	-7.15	0.000	HS
EMG concave	45.778 $\pm$ 6.078	39.333 $\pm$ 4.662	3.167	0.004	S

HS, highly significant; S, significant; SEMG, surface electromyography.

**Table 3 Comparison between initial Risser score and Risser score after 1 year**

Initial Risser's	Risser's after 1 year [N (%)]				Total
	0	1	2	3	
0	3 (10.00)	11 (36.67)	0 (0.00)	0 (0.00)	14 (46.67)
1	0 (0.00)	0 (0.00)	3 (10.00)	0 (0.00)	3 (10.00)
2	0 (0.00)	0 (0.00)	7 (23.33)	2 (6.67)	9 (30.00)
3	0 (0.00)	0 (0.00)	0 (0.00)	4 (13.33)	4 (13.33)
Total	3 (10.00)	11 (36.67)	10 (33.33)	6 (20.00)	30 (100.00)
Wilcoxon signed-ranks test					
Z			-4.000		
P-value			0.000		

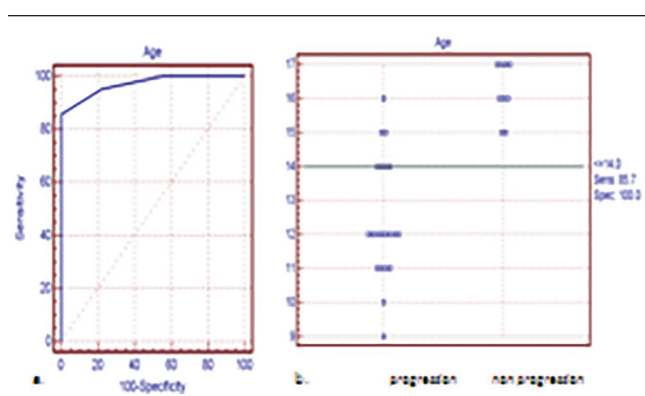
the most sensitive parameter followed by SEMG. The highest positive predictive values (100%) were seen for age at a cutoff of 14 years, iRisser's score at a cutoff of 1 or less, and convex SEMG activity with a cutoff of 80 or more; the least negative predictive factor was the initial Cobb's angle (66.7%) (Table 4 and Figs 2a,b, 3a,b, 4a,b, 5a,b and 6a,b).

**Table 4 Receiver-operating character curve of age, Cobb's angle, initial Risser's stage, and surface electromyography for predictive value of curve progression**

Variant	Cutoff	Sensitivity	Specificity	PPV	NPV	Accuracy
Age	14	85.7	100.0	100.0	75.0	0.971
iCobb's angle	≤20	95.2	22.2	74.1	66.7	0.534
iRisser's stage	≤1	81	100	100	69.2	0.947
SEMG convex	>80	90.5	100.0	100.0	81.8	0.966
Concave	≤45	90.2	66.7	87.0	85.7	0.807

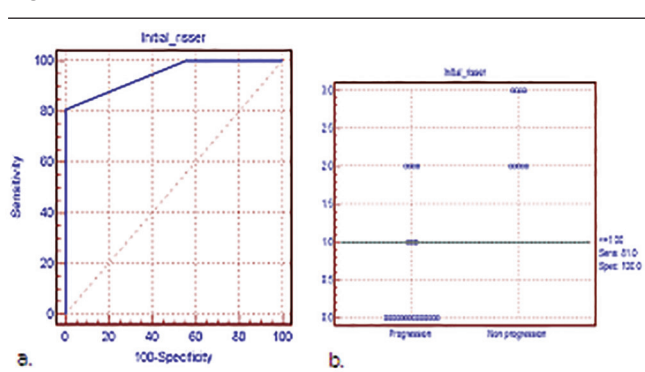
iCobb's, initial Cobb's; iRisser's, initial Risser's; NPV, negative predictor value; PPV, positive predictor value; SEMG, surface electromyography.

**Figure 2**



(a) Receiver-operating character curve for age. (b) Cutoff value, specificity, and sensitivity for both the progressive and the nonprogressive group.

**Figure 4**

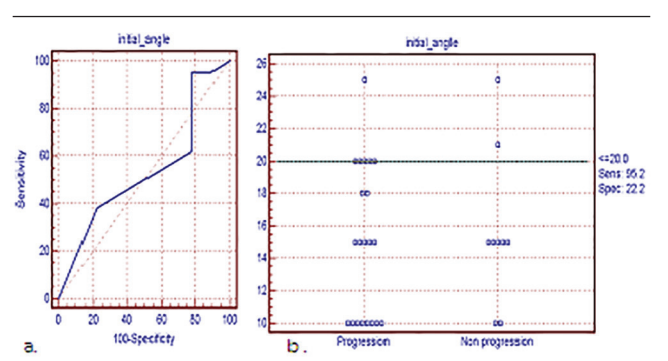


(a) Receiver-operating character curve for initial Risser. (b) Cutoff value, specificity, and sensitivity for both the progressive and the nonprogressive group.

On studying our second aim, which was correlation of the studied parameters with curve progression (the percentage of change in Cobb's angle), we found that curve progression was significantly negatively correlated with age and iRisser's score and significantly positively correlated with the initial SEMG (convex side). That is to say that the younger the child with immature bone, the more likely he or she is to have a progressive curve; on the other hand, the greater the SEMG activity on the convex side, the more the liability for curve progression (Table 5).

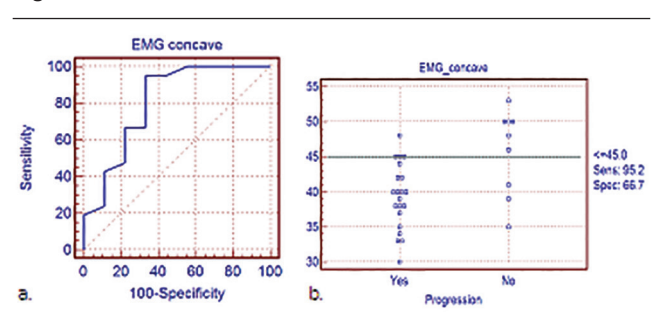
As we used SEMG as a new predictor of curve progression, we tried to emphasize its role by detailed studying of the different correlations of SEMG with the other tested parameters age and the iRisser staging score, wherein it showed a statistically negative highly significant correlation with both. In contrast, a significant positive correlation was found with the initial Cobb's angle (Table 6). Further, on studying the correlation of SEMG activity on the convex side with all parameters after 1 year, we found a high significant negative correlation with age and Risser's score and significant positive correlation with Cobb's angle ( $r = -0.598, P < 0.001$ ;  $r = -0.474, P < 0.01$ ; and

**Figure 3**



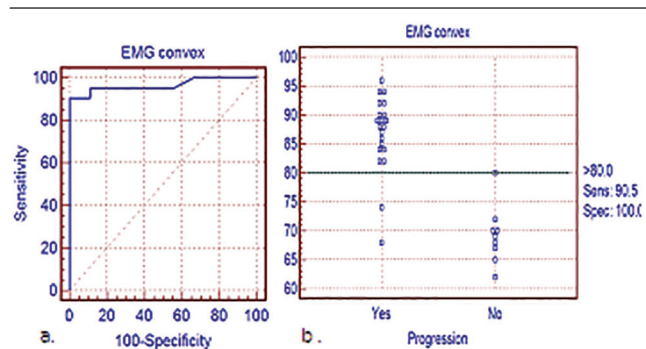
(a) Receiver-operating character curve for initial angle. (b) Cutoff value, specificity, and sensitivity for both the progressive and the nonprogressive group.

**Figure 5**



(a) Receiver-operating character curve for surface electromyography (SEMG) concave. (b) Cutoff value, specificity, and sensitivity for both the progressive and the nonprogressive group.

Figure 6



(a) Receiver-operating character curve for surface electromyography (SEMG) convex. (b) Cutoff value, specificity, and sensitivity for both the progressive and the nonprogressive group.

**Table 5 Correlation of curve progression versus age, Risser’s score, and surface electromyography**

Curve progression (% of change in Cobb’s angle)	Curve progression (% of change in Cobb’s angle)		Significance
	R	P-value	
Age	-0.666	0.000*	HS
Initial risser score	-0.628	0.000*	HS
SEMG convex side (initial)	0.651	<0.001*	HS

HS, highly significant.

**Table 6 Correlation between surface electromyography on the convex side and age, initial Risser’s score, and initial Cobb’s angle**

Variants	SEMG convex		Significance
	R	P-value	
Age	-0.743	<0.001*	HS
iRisser’s score	-0.740	<0.001*	HS
iCobb’s angle	0.437	0.471	S

HS, highly significant; iCobb’s, initial Cobb’s; iRisser’s, initial Risser’s; s, significant; SEMG, surface electromyography.

$r = 0.456, P < 0.01$ , respectively), highlighting the value of performing an SEMG initially and during follow-up.

## Discussion

A problem in finding useful predictors for the timing of pubertal growth spurt is that several indicators are useful only for large groups of adolescents. A combination of several indicators of growth and curve progression can help the orthopedic surgeon in planning the treatment of AIS [20,21].

This study provides a concise outline of several indicators of growth and curve progression in order to provide a clear overview of which indicators are useful in predicting the timing of the pubertal growth spurt and therefore the timing of possible scoliosis progression.

Previously, many authors have studied various indicators of curve progression as mentioned before, but in this study we chose age, SEMG on either side of the scoliotic curve, and Risser’s staging score and Cobb’s angle before and after a rehabilitation program of 1 year as different predictors in the progression of AIS.

SEMG was used because of its greater safety and practicality compared with needle EMG, as surface and needle EMG recordings of the scoliotic curve show qualitatively the same EMG activity asymmetry [12].

Patients were evaluated clinically and radiologically to rule out other causes of adolescent scoliosis. The angle of the scoliotic curve was assessed by Cobb’s method in sitting and standing position; this has been established earlier as a reliable tool for diagnosis and follow-up of AIS. The range of the initial angle was 10–25° in all patients without spinal rotation. Our study stated that initial assessment of Cobb’s angle was the most sensitive parameter for detecting curve progression. This was in accordance with most of the previous studies in which it was used as a predictor of curve progression [1–3].

Skeletal maturity was determined by Risser’s staging, which is known as an acceptable prognostic tool in the diagnosis of growth. The protocol chosen was the A–P approach to ensure more reliable evaluation of apophyseal ossification of the iliac crest. This issue was confirmed before by Izumi [4]. He had found distortion on the PA films to be so significant that he concluded that ‘...the appearance of the iliac apophysis on posteroanterior radiograph cannot be used as a reliable indicator of skeletal maturity.’ All patients’ Risser’s scores were less than stage 4 to ensure continuous trunk growth, as it is known that Risser’s stage 5 is a point at which there is cessation of curve progression [17]. Furthermore, 14 patients started at stage 0 and 11 of them reached stage 1, which was parallel to the increase in Cobb’s angle at the end of the study. This was in accordance with previous studies [17]. In this study Risser’s staging score was used to follow-up pubertal growth and to predict curve progression by monitoring the change in Risser’s score with Cobb’s angle. Results showed that iRisser’s score was significantly negatively correlated with curve progression. Accordingly, a possible link might exist between progression of scoliotic deformity and rate of skeletal growth. Indeed, 16 adolescents throughout this study revealed an increase in Risser’s score: 14 of them were in the progressive group, and only two adolescents were in the nonprogressive group.

Others [20–23] also suggested that Risser’s sign, together with the apical vertebral rotation, and spinal

length are important factors for the prediction of progression in girls with AIS. Our study reconfirmed this finding and concluded that Risser's score is 'a specific radiographic parameter when evaluating the growth potential in children with scoliosis with a 100% positive predictor value for curve progression'.

Nineteen patients complained of dorsal pain, which could be due to muscle imbalance. The imbalance may cause increased pressure on the intervertebral discs and lead to eventual pain [24]. Moreover, there is evidence of an association between asymmetrical muscle activation and scoliosis with back pain.

The erector spinae muscle activation was recorded on both sides of the scoliotic curve in sitting and standing positions to evaluate muscle activity at rest and on muscle loading when balance is needed to keep an upright posture. These positions were used as they correspond to easy natural physiological human statures [9]. Muscle activity was compared on either side in the two positions and there was high statistically significant difference between the two sides in favor of the convex side. Moreover, the SEMG (convex) was found to be correlated with all of the tested parameters (age, Risser's score, and Cobb's angle) initially and after 1 year, and correlated with the curve progression giving a high value for this evaluation and its great value in follow-up in combination with other parameters. This was confirmed previously by most EMG studies who showed decreased EMG activity on the concave side and increased EMG activity on the convex side of the paraspinal muscles in patients with scoliosis at rest [9,25]. Recently, it was debated whether altered EMG activity of the paraspinal muscles in patients with scoliosis at rest is a result of the necessity to balance the deviated spine or an essential element of scoliosis [26]. Moreover, to elaborate the predictor value of SEMG in AIS, another significant positive correlation between SEMG activity and curve progression assumed a close relation between muscle imbalance and severity of scoliosis. This could be explained as the higher activity at the apex is mandatory to overcome the increased angulation of the vertebral column, which occurred as a result of skeletal growth, which was confirmed by the increased Risser's score in our study, which was also documented by other authors, who stated that SEMG can be used as an objective examination in evaluating the difference in muscle activity on both concave and convex sides for patients with AIS as well as for assessment of progression [27,28].

On applying the ROC curve to determine the most predictive parameter in curve progression, we found age, iRisser's staging, and SEMG of the convex side to be the most specific, and the initial Cobb's angle to be the most sensitive, followed by SEMG.

This cohort study provided an outline of several indicators of curve progression in patients with AIS. Useful indicators should be easy to use, fast, and should not place a large burden on the patient or the clinician. For example, SEMG measurement of the paraspinal muscles is a highly promising method but it is fairly time-consuming [9,29].

---

## Conclusion and recommendations

This cohort study had enabled us to clarify the associations between muscle activity asymmetry, growth velocity, and changes in the progression of scoliosis using different parameters.

Initial Cobb's angle was the most sensitive predictor, followed by SEMG on the convex side. We recommend measurement of either Cobb's angle or SEMG due to their feasibility in follow-up for progression of AIS.

---

## Acknowledgements

The authors thank Dr. Abdelaziz Al Garf, statistics specialist, for his tremendous help in statistical analysis.

## Financial support and sponsorship

Nil.

## Conflicts of interest

There are no conflicts of interest.

---

## References

- 1 Busscher I, Wapstra FH, Veldhuizen AG. Predicting growth and curve progression in the individual patient with adolescent idiopathic scoliosis: design of a prospective longitudinal cohort study. *BMC Musculoskelet Disord* 2010; **11**: 93.
- 2 Yrjönen T, Ylikoski M. Effect of growth velocity on the progression of adolescent idiopathic scoliosis in boys. *J Pediatr Orthop B* 2006; **15**:311–315.
- 3 Little DG, Sussman MD. The Risser sign: a critical analysis. *J Pediatr Orthop* 1994; **14**:569–575.
- 4 Izumi Y. The accuracy of Risser staging. *Spine (Phila Pa 1976)* 1995; **20**:1868–1871.
- 5 Sanders JO, Browne RH, Cooney TE, Finegold DN, McConnell SJ, Margraf SA. Correlates of the peak height velocity in girls with idiopathic scoliosis. *Spine (Phila Pa 1976)* 2006; **31**:2289–2295.
- 6 Sanders JO. Maturity indicators in spinal deformity. *J Bone Joint Surg Am* 2007; **89**(Suppl 1):14–20.
- 7 Nault ML, Parent S, Phan P, Roy-Beaudry M, Labelle H, Rivard M. A modified Risser grading system predicts the curve acceleration phase of female adolescent idiopathic scoliosis. *J Bone Joint Surg Am* 2010; **92**:1073–1081.
- 8 Staudenmann D, Roeleveld K, Stegeman DF, van Dieën JH. Methodological aspects of SEMG recordings for force estimation — a tutorial and review. *J Electromyogr Kinesiol* 2010; **20**:375–387.
- 9 Cheung J, Veldhuizen AG, Halbertsma JP, Maurits NM, Sluiter WJ, Cool JC, Van Horn JR. The relation between electromyography and



- growth velocity of the spine in the evaluation of curve progression in idiopathic scoliosis. *Spine (Phila Pa 1976)* 2004; **29**:1011–1016.
- 10 Hawes MC, O'Brien JP. The transformation of spinal curvature into spinal deformity: pathological processes and implications for treatment. *Scoliosis* 2006; **1**:3.
  - 11 Stokes IA, Burwell RG, Dangerfield PH, IBSE. Biomechanical spinal growth modulation and progressive adolescent scoliosis — a test of the 'vicious cycle' pathogenetic hypothesis: summary of an electronic focus group debate of the IBSE. *Scoliosis* 2006; **1**:16.
  - 12 Candotti B, Pasni M, Melo M, La Torre M. Assessment of neuromuscular activation in individuals with scoliosis using surface electromyography. *Rev Bras Fisioter* 2008; **12**:13–19.
  - 13 Lenke LG. Lenke classification system of adolescent idiopathic scoliosis: treatment recommendations. *Instr Course Lect* 2005; **54**:537–542.
  - 14 Beauchamp M, Labelle H, Grimard G, Stanciu C, Poitras B, Dansereau J. Diurnal variation of Cobb angle measurement in adolescent idiopathic scoliosis. *Spine (Phila Pa 1976)* 1993; **18**:1581–1583.
  - 15 Cheung J, Wever DJ, Veldhuizen AG, Klein JP, Verdonck B, Nijluning R, *et al.* The reliability of quantitative analysis on digital images of the scoliotic spine. *Eur Spine J* 2002; **11**:535–542.
  - 16 Korovessis PG, Stamatakis MV. Prediction of scoliotic Cobb angle with the use of the scoliometer. *Spine (Phila Pa 1976)* 1996; **21**:1661–1666.
  - 17 Noordeen MH, Haddad FS, Edgar MA, Pringle J. Spinal growth and a histologic evaluation of the Risser grade in idiopathic scoliosis. *Spine (Phila Pa 1976)* 1999; **24**:535–538.
  - 18 Patel K. Quatd in corrective exercise (chapter 11). H Aarnold, editor. Amazon. 5th ed. UK: Corrective Exercise: A practical Approach; 2009. P130–P166.
  - 19 Kisner C. *Therapeutic exercise: foundations and technique* (chapter 16). 4th ed. Philadelphia: FA Davis; 2002. P638–P677.
  - 20 Dimeglio A, Canavese F. The growing spine: how spinal deformities influence normal spine and thoracic cage growth. *Eur Spine J* 2012; **21**:64–70.
  - 21 DiMeglio A, Canavese F, Charles YP. Growth and adolescent idiopathic scoliosis: when and how much? *J Pediatr Orthop* 2011; **31**(Suppl):S28–S36.
  - 22 Canavese F, Dimeglio A. Normal and abnormal spine and thoracic cage development. *World J Orthop* 2013; **4**:167–174.
  - 23 Zhang Y, Yang Y, Dang X, Zhao L, Ren J, Zhang L, Sun J. Factors relating to curve progression in female patients with adolescent idiopathic scoliosis treated with a brace. *Eur Spine J* 2015; **24**:244–248.
  - 24 Rutkowska-Kucharska A, Szpala A, Pieciuk E. Symmetry of muscle activity during abdominal exercises. *Acta Bioeng Biomech* 2009; **11**:25–30.
  - 25 Guo LY, Wang YL, Huang YH, Yang CH, Hou YY, Harn HI, You YL. Comparison of the electromyographic activation level and unilateral selectivity of erector spinae during different selected movements. *Int J Rehabil Res* 2012; **35**:345–351.
  - 26 Reuber M, Schultz A, McNeill T, Spencer D. Trunk muscle myoelectric activities in idiopathic scoliosis. *Spine (Phila Pa 1976)* 1983; **8**:447–456.
  - 27 Hopf C, Scheidecker M, Steffan K, Bodem F, Eysel P. Gait analysis in idiopathic scoliosis before and after surgery: a comparison of the pre- and postoperative muscle activation pattern. *Eur Spine J* 1998; **7**:6–11.
  - 28 Du HG, Ye SL, Xu JY, Jiang Z, Song HQ, Yu JW. Application of surface electromyography in the treatment of adolescent idiopathic scoliosis with traditional spinal balanced therapy. *Zhongguo Gu Shang* 2013; **26**:914–917.
  - 29 Cheung J, Halbertsma JP, Veldhuizen AG, Sluiter WJ, Maurits NM, Cool JC, van Horn JR. A preliminary study on electromyographic analysis of the paraspinal musculature in idiopathic scoliosis. *Eur Spine J* 2005; **14**:130–137.