Moussa *et al.*
Egyptian Rheumatology and Rehabilitation (2024) 51:16
https://doi.org/10.1186/s43166-024-00250-z

Egyptian Rheumatology and Rehabilitation

RESEARCH

Open Access

Efficacy of adipose—derived stromal vascular fraction in treatment of osteoarthritis: an experimental study

Sherine Alaa El Din Mohamed Moussa[1], M. Gamal El Din Zaki[1], Manal Osman Mohamed[1], Asmaa A Abo Zeid[2] and Dina A. Farrag[1*]

Abstract

Background Osteoarthritis OA is a common progressive disabling disease. Current research aims at finding therapies to prevent its progression. In this work, we assessed the therapeutic role of intra-articular injection of stromal vascular fraction SVF in collagenase induced knee OA in rats.

Results Post right Knee OA induction in 42 Wistar rats, histopathological examination and quantification of articular cartilage degeneration using Mankin's score revealed degenerative changes were significantly higher in untreated Group II compared to SVF treated Group III at 1 month (10.75 ± 0.50 and 2.50 ± 0.53, $P = 0.001$) and 2 months (8.50 ± 0.58, 0.50 ± 0.53, $P = 0.001$), respectively. Morphometric computerized image analysis revealed a significant difference between treated, untreated and healthy control group I regarding chondrocyte cellular count, articular cartilage thickness and optical density OD of the cartilage ($P < 0.001$). Group II contained the least chondrocyte cellular count. Also, articular cartilage thickness at 2 months was significantly less in Group II compared to SVF treated group ($P < 0.001$). The OD in Safranin-stained slides, as an indicator of proteoglycan content of the matrix, was highest in Group I followed by Group III and lowest in Group II with a highly significant difference between untreated and treated groups at 1 month (67.32 ± 4.25, 81.77 ± 3.09, $P = 0.000$) and 2 months (71.60 ± 3.49, 83.26 ± 5.47, $P = 0.000$), respectively.

Conclusion Treatment with adipose-derived SVF decreased the development of articular cartilage degenerative changes at early stages of induced OA in rats. Later, on follow-up, the preserved articular cartilage thickness, cellular count and increased proteoglycan content rendered SVF a promising regenerative therapy for Knee OA.

Keywords Osteoarthritis, Stromal vascular fraction, Experimental animals, Intraarticular injection, Cartilage repair

Background

Knee Osteoarthritis (OA) represents a global burden, yet most of the available treatments are only symptomatic [1]. Stem cell-based therapeutics are promising regenerative modalities for Knee OA [2, 3]. During in vitro chondrogenic differentiation of mesenchymal stem cells (MSCs), normal components of articular cartilage like glycosaminoglycans and collagen type II are produced [4]. Different sources of MSCs have been examined for their regenerative capability on articular cartilage and delaying Knee OA progression [5, 6]. Those generated from the bone marrow have been linked with improvements in pain, function, and restoration of normal articular cartilage morphology [7, 8]. However adipose derived tissue, whether stromal vascular fraction (SVF) or adipose-derived stem cells (ADSCs), has from

*Correspondence:
Dina A. Farrag
dinaaboubakr@yahoo.com; drdina.farrag@med.edu.asu.eg
[1] Physical Medicine, Rheumatology & Rehabilitation Department, Faculty of Medicine, Ain Shams University, Cairo, Egypt
[2] Histology and Cell Biology Department, Faculty of Medicine, Ain Shams University, Cairo, Egypt

100 up to 500 times more stem cells than the bone marrow [9]. Moreover, lipoaspirates are easier to obtain with decreased incidence of complications and morbidity [10].

The SVF is an aqueous fraction obtained from the enzymatic digestion of lipoaspirate. It contains ADSCs, and a combinations of endothelial progenitor cells (EPCs), endothelial cells (ECs), macrophages, smooth muscle cells, lymphocytes, pericytes and pre-adipocytes among others [9]. It has shown beneficial results in regenerative and reconstructive medicine [10, 11]. Although SVF shares the same properties as ADSCs, it doesn't need to be cultured and can be isolated and freshly used in the same setting [12].

Studies have shown the feasibility and safety of ADSCs as an ideal option for Knee OA treatment [12, 13]. Yet, the efficacy of using fresh SVF without expansion for OA treatment is still under research. In this work we studied the value of SVF treatment in experimentally induced Knee OA in rats.

Materials and methods

All animal handling procedures and sacrifices in this experimental study were approved by the Local Ethical Committee and have therefore been performed in accordance with the ethical standards laid down in the 1964 Declaration of Helsinki and its later amendments.

Study procedure

This experimental study included 48 Wistar Albino rats; 42 female rats aged 8 to 10 weeks and weighing 150 to 200 g for OA induction. Adipose tissue, obtained from inguinal pad of fat of 6 male rats, aged 6 to7 weeks and weighing almost 100 g each, was processed to produce SVF.

All rats were acclimatized for 1 week. Not more than 3 rats were kept in each cage. They were given free access to food and water, a standard diet, and kept under controlled temperature (22–24 °C). They were exposed to 12 h day/ night light cycle, not exposed to unnecessary pain and only when necessary were sacrificed by overdose of anesthesia, the remnants disposed of by the incinerator.

Induction of OA

Right Knee OA was induced in all 42 adult female rats after they were anesthetized by injecting Ketamine 60 mg/kg intraperitoneal. Intra-articular injection of 50ul of type II collagenase (Sigma, USA) solution at a concentration of 0.4 mg/l dissolved in saline using 26 G insulin syringe was inserted through the patellar ligament into the joint space. One injection was received on day 0 and day 7 [14].

Female rats were then grouped into:

Group I: Healthy controls: Normal healthy left knees were injected with saline. 10 samples were selected randomly from rats from the other 2 groups.

Group II: Untreated Induced OA: 22 rats with induced right Knee OA and not treated, act as OA control group. Two rats were sacrificed for proof of OA after 2 weeks of induction.

Group III: Treated SVF Group: 20 rats with induced right Knee OA treated with SVF (100ul intra-articular after proof of OA induction at week 2)

Rats from untreated and treated groups were evenly divided and 10 rats from each group were sacrificed for assessment at 1 and 2 months post OA induction respectively.

SVF preparation

After anesthetizing the six male rats, the inguinal pad of fat was dissected under complete aseptic conditions and placed in a falcon tube containing phosphate buffer saline (PBS) with 2% penicillin/streptomycin. The specimens were washed extensively with PBS and large blood vessels in the tissue were excised. After wash, tissue was cut into small fragments, digested with 0.1% collagenase type I (Sigma, USA) for 45–60 min and incubated at 37 °C with intermittent shaking every 10 min. Collagenase activity was blocked by 10 ml of fetal bovine serum (FBS). Suspension was then filtered by 100 um nylon mesh and centrifuged at 1800 rpm for 10 min at 25 °C. After digestion, cells were suspended in PBS. Each 3 gm of fat yielded 10^6 cells/ ml counted manually. SVF was prepared in a way that is not immunogenic to the recipient rats [15].

Flow cytometric characterization of isolated SVF:

The CD45-FITC, CD44-FITC and CD34-FITC were used to stain the SVF cells. The cells were suspended in PBS and the count adjusted to 10^6 /ml. The Navios software (Beckman Coulter) was used to analyze flow cytometry data [15]. In this work flow cytometric analysis and characterization of SVF cells revealed SVF stem cells stained with hematopoietic markers (CD34 and CD45) were negative and were positive for MSC markers (CD44).

Detection of Y-chromosome in female rats using quantitative PCR (qPCR)

After one month, 1 rat was sacrificed from untreated group II and another from the treatment group III for detection of Y chromosome in the female articular cartilage using PCR. After bone tissue was homogenized and suspended in PBS, DNA was extracted and Gene expression analyzed. Quantification of sex-determining region of the Y chromosome (SRY) was amplified from extracted DNA using a specific sequence primer

and the QuantiTect SYBR Green PCR Kit (Qiagen, Germany) [16].

Histopathological and morphometric analysis

Whole knee joints were fixed in 10% buffered formalin and decalcified in ethylenediaminetetraacetic acid (EDTA). Samples were embedded by immersing in fresh molten paraffin. Sections were cut by microtome with 5 μm thickness mounted on glass slides. Slides were stained with Hematoxylin and Eosin. Proteoglycan content was examined by Safranin-O / Fast green staining. Twenty-five to thirty images per sample were taken by an Olympus B X61 microscope (Olympus).

Degenerative changes of the articular cartilage were assessed and calculated:

Semi – quantitatively; using the slightly modified Mankin's histological score [17] where histological evidence of cartilage degeneration was evaluated by the structural changes of articular cartilage (0, normal; 1, surface irregularities; 2, surface irregularities and pannus; 3, clefts to transitional zones; 4, clefts to calcified zones; and 5, complete disorganization) and the cell status (0, normal; 1, diffuse hypercellularity; 2, cloning; and 3, hypocellularity), matrix staining(0, normal; 1, mild reduction; 2, moderate reduction; 3, severe reduction; 4, no staining), tide mark integrity (0, intact; 1, destroyed). Total score ranged from 0–13, where 0 was normal and the higher the score, the more severe the degeneration [18].

Quantitatively; using computerized image analysis where chondrocyte count, articular cartilage thickness and optic density of matrix were assessed.

Statistical analysis

Data were analyzed using the Statistical Package for Social Science (IBM SPSS) version 23. The quantitative data were presented as mean, standard deviations. Comparison between more than two independent groups with quantitative data and parametric distribution was done using One Way ANOVA test, followed by post hoc analysis using LSD test. For non-parametric data distribution, it was done using Kruskall Wallis test followed by post hoc analysis using Mann–Whitney test. The confidence interval was set to 95% and the margin of error accepted was set to 5%. The P-value > 0.05 was non-significant (NS), P-value ≤ 0.05: significant (S), P-value ≤ 0.01: highly significant (HS).

Results

Expression of SYR gene in tested samples by real time PCR (qPCR)

High expression of SYR gene was observed in the treated female rat sample, while the untreated sample showed negative expression of SYR gene.

Histopathological findings of the examined knee joint specimens in the three groups revealed

Light microscopy results

The healthy group's articular cartilage surface in group I was smooth. The chondrocytes were grouped into four typical zones: the superficial zone, which had chondrocytes arranged with their longitudinal axis parallel to the articular surface; the middle zone, which had chondrocytes scattered and round-shaped; the deep cartilage zone which had cells grouped into parallel columns perpendicular to the articular surface; and the calcified zone. A transverse tidemark line separated the deep zone from the calcified zone (Fig. 1A). The articular surface had

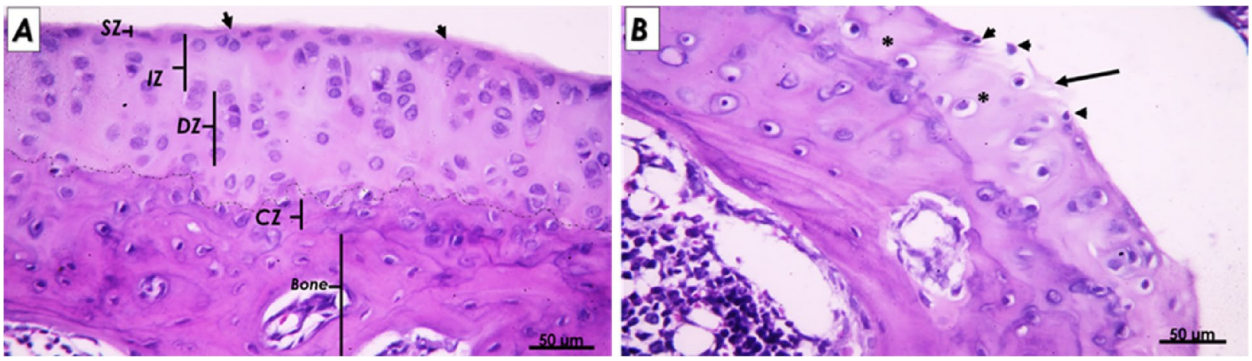

Fig. 1 **A** The histopathological examination of healthy control demonstrated that the surface of the articular cartilage was regular and smooth (▲). The chondrocytes are arranged into 4 zones: Superficial zone (SZ); intermediate zone (IZ); deep zone (DZ); and calcified cartilage zone (CZ). A transverse tidemark (dashed line) can be noticed. **B** Section of Knee joint showing early degenerative changes in cartilage 2 weeks after induction of arthritis. The surface of the articular cartilage shows fibrillations, irregularity (↑) and areas with shed off apoptotic chondrocytes (arrowhead). The cartilage matrix is pale stained (*). (H&E × 400)

early degenerative alterations two weeks after OA induction. These changes included rough surface with erosions and fibrillation, chondrocyte clusters formed, and apoptotic chondrocyte shedding (Fig. 1B).

In the untreated Group II, one month after induction, marked irregularities of the articular surface with complete loss of chondrocytes organization and marked degeneration was observed (Fig. 2A). After 2 months, Group II articular cartilage still showed microscopic signs of OA with surface irregularities, cellular disorganization, and reduced knee hyaline cartilage thickness (Fig. 2C).

At one month, Group III displayed partial articular cartilage regeneration. The cartilage matrix was intact, and the articular surface appeared regular. Although chondrocytes were not highly structured, they nonetheless looked viable (Fig. 2B). However, after two months, Group III displayed articular cartilage histological structural regeneration that was on par with the healthy group. Smooth and normal articular cartilage was present. The cartilage matrix remained intact, and viable chondrocytes filled in the lacunar spaces, forming the ordinary four layers (Fig. 2D).

The synovial membrane of Group I showed a flat intimal lining made up of one to two layers of synovial cells. A few numbers of dispersed blood vessels and adipose cells made up the subintimal connective tissue. The intimal lining thickened and the subintimal connective tissue had a significant inflammatory cellular infiltration with dilated and congested blood vessels two weeks after OA induction (Fig. 3a). Group II exhibited a noticeable thickening of the intimal lining and a subintimal connective tissue composed of thick collagen bundles that had been invaded by inflammatory cells after one month. Group III showed a comparatively thin intima lining, a few dispersed inflammatory cells in the subintimal stroma, and a noticeable decline in collagen fiber bundles. At two months, Group II displayed thin intimal lining, but thicker collagen bundles with dispersed inflammatory cells and dilated blood vessels were still visible in the subintimal connective tissue. Group III showed a comparatively thin intimal lining, few inflammatory cells,

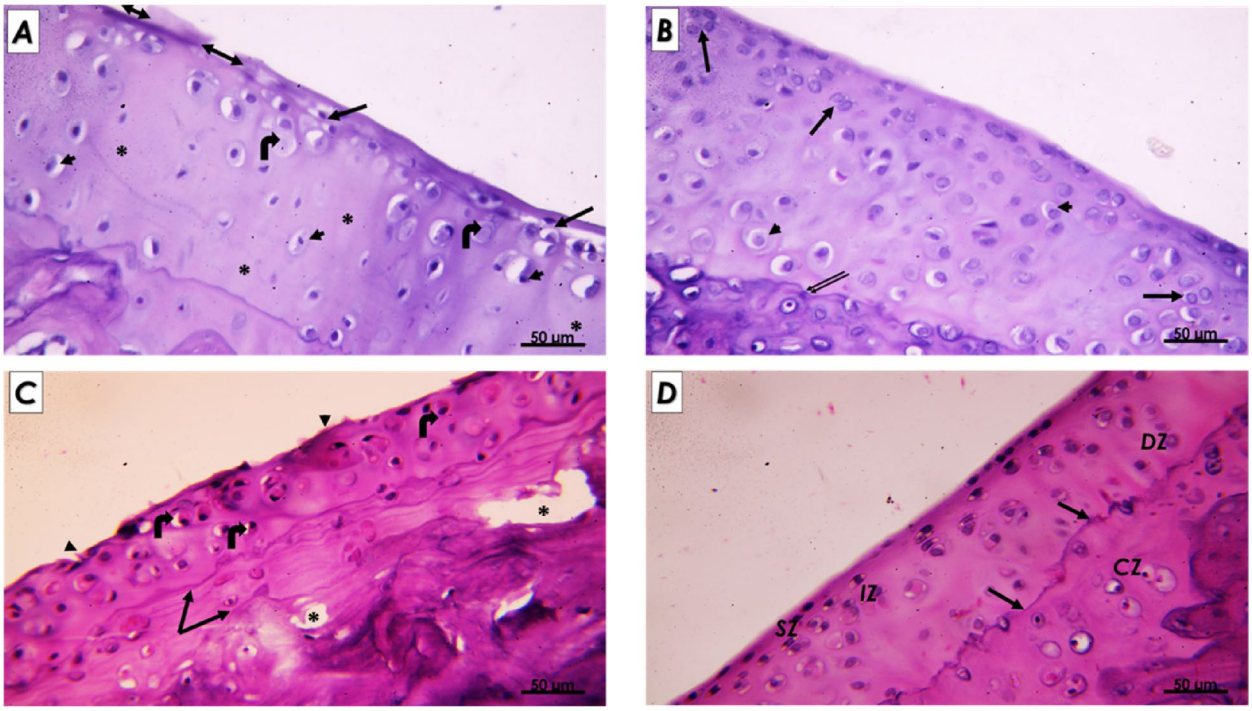

Fig. 2 Sagittal Section in rat knee stained with H&E showing comparison between induced arthritis untreated group II and treated group III. **A** Group II at 1 month showing surface erosions (double headed arrows), loss of chondrocytes' arrangement into usual 4 zones, many lacunae appear having degenerated chondrocyte with small darkly stained nuclei (▲) or without nuclei (curved arrows), areas of chondrocytes' loss (*). Clusters of chondrocytes can be noticed near the articular surface (↑). The tidemark is ill-defined. **B** Group III at 1 month showing smooth and regular articular surface, viable chondrocytes fill all the lacunae (▲) but organized irregularly. Many isogenous clusters can be noticed (↑). Evident tidemark (↑↑) can be seen. **C** Group II at 2 months still showed microscopic signs of osteoarthritis with surface irregularities and chondrocytes appear degenerated with shrunken cytoplasm and pyknotic eccentric nuclei (curved arrows). Duplication of the tidemark line (↑), superficial fibrillation (head arrows), and subchondral cysts (*) are clearly seen. **D** Group III at 2 months showing cartilage regeneration is observed with smooth articular surface. Chondrocytes are rearranged in the four usual zones (SZ), (IZ), (DZ), and (CZ) with tidemark (arrows). (H&E, X400)

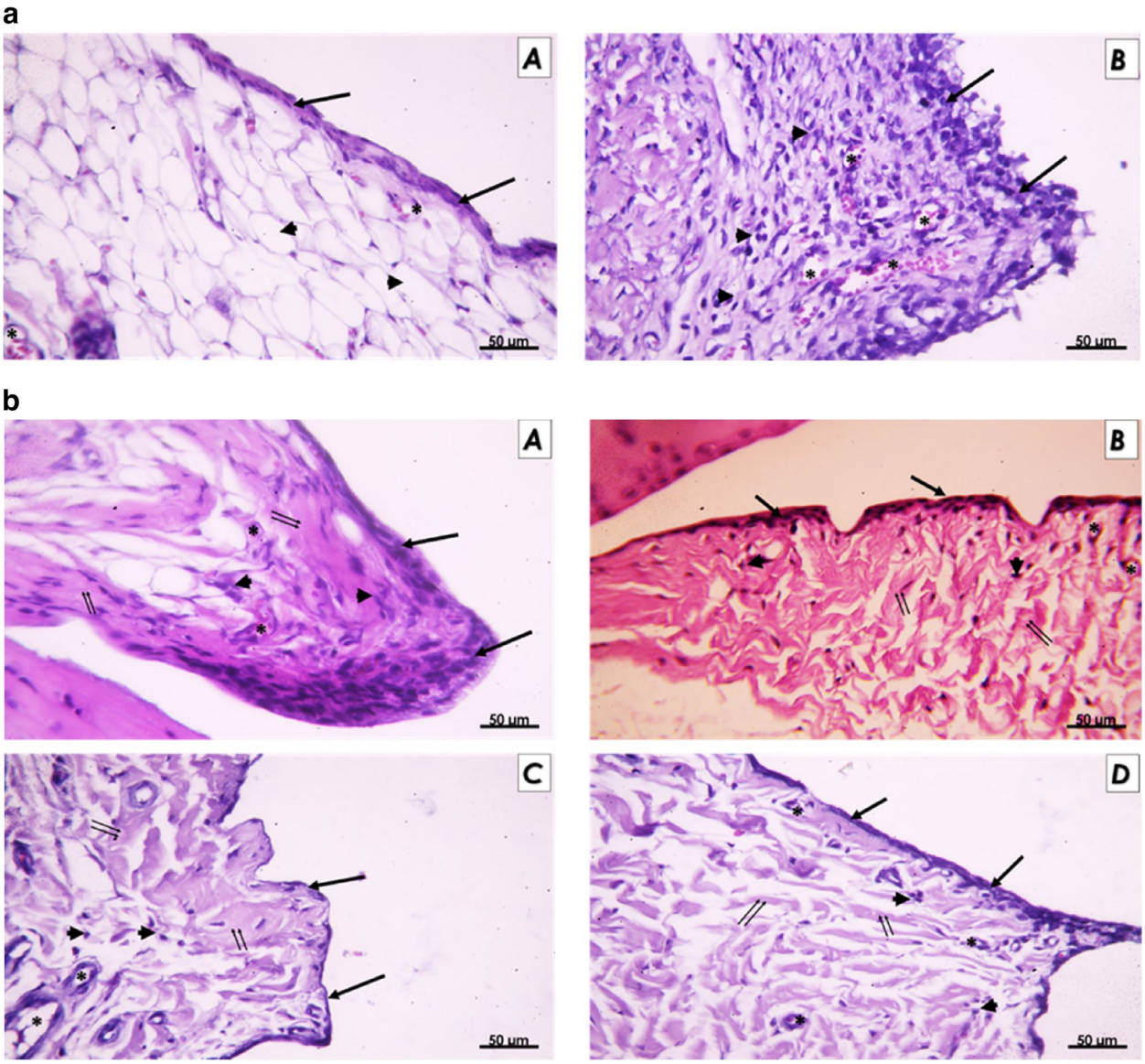

Fig. 3 **a** A. Healthy group showing synovial membrane is covered by two layers of thin flat intimal cells (↑). The subintimal connective tissue consists of fat cells (▲) with few blood capillaries (*). B. Group II 2 weeks after osteoarthritis induction showing thickened synovial membrane with stratified cell layers (↑), and subintimal connective tissue infiltrated extensively by inflammatory cells (▲) with many dilated congested blood vessels (*). (H&E, X400). **b** A. Group II at 1 month showing thickened synovial membrane with stratified layers of intimal lining (↑), and subintimal connective tissue with thick collagen bundles (↑↑), inflammatory cells infiltrate (▲) and dilated congested blood capillaries (*). B. Group III at 1 month showing synovial membrane with relatively thin intima consists of 2 layers of flat cells (↑). Notice the subintimal connective tissue is formed of irregularly arranged thick collagen bundles (↑↑) and scattered few inflammatory cells (▲). C. Group II at 2 months showing synovial membrane with moderately thin intima (↑), but the subintimal connective tissue still contains thick collagen bundles (↑↑), mononuclear cellular infiltrate (▲) with dilated blood capillaries (*). D. Group III at 2 months showing synovial membrane with thin intima (↑). The subintimal connective tissue is formed of irregularly arranged thin collagen bundles (↑↑) and scattered few mononuclear cells (▲) with thin-walled blood capillaries (*). (H&E, X400)

thin collagen fibers, and a few dispersed blood vessels (Fig. 3b).

The uniform orange color of the articular cartilage matrix was observed upon examination of Safranin O-stained sections from the healthy group (Group I) (Fig. 4A). When compared to Group I, Group II's superficial and deep cartilage layers showed a noticeably faint staining intensity of Safranin O stain after one month (Fig. 4B). Group III's staining intensity of the cartilage matrix seemed to have increased, particularly in the

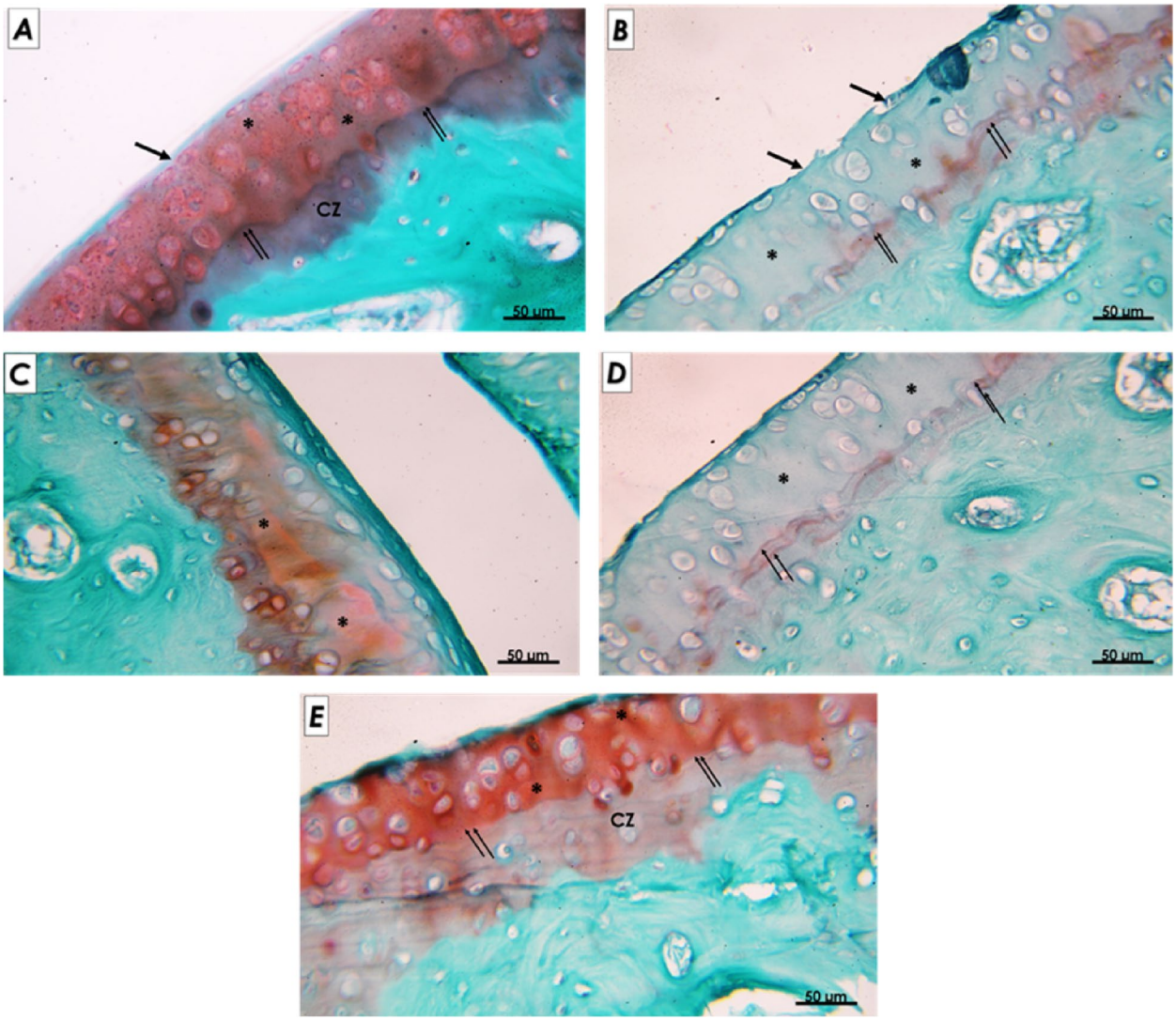

Fig. 4 Photomicrograph of section in adult female rat knee joint stained with Safranin O stain. **A** Healthy group showing regular and smooth articular cartilage (↑) with homogenous intense orange staining of the matrix of the articular cartilage (*) with apparent tidemark line (↑↑) separating the (DZ) from the (CZ). **B** Group II at 1 month showing irregular surface and erosion of articular cartilage (↑) with marked decrease in orange staining of the matrix of the cartilage (*). Notice duplication of tidemark (↑↑). **C** Group III at 1 month exhibits relative increased intensity staining of Safranin O stain of the cartilage matrix particularly in the deep zone (*). **D** Group II at 2 months still show faint staining intensity of cartilage matrix (*). Notice duplication of tidemark (↑↑). **E** Group III at 2 months revealed increase in intensity of the Safranin O stain of the cartilage matrix both in the superficial and deep zones (*). Notice apparent tidemark line (↑↑) separating the deep cartilage zone from the calcified zone (CZ). (Safranin O stain, X 400)

deep zone after one month (Fig. 4C). After two months, Group II continued to show slight staining intensity of the cartilage's matrix and apparent tidemark duplication (Fig. 4D). However, group III showed that the cartilage matrix's Safranin O stain intensity had increased in both the superficial and deep zones (Fig. 4E).

Modified Mankin score (MS)

There was a statistically significant difference between the studied groups regarding MS with p-value < 0.001. A significant difference was observed comparing untreated Group II to SVF treated group at 1 month (10.75 ± 0.50 and 2.50 ± 0.53, $P = 0.001$) and 2 months (8.50 ± 0.58, 0.50 ± 0.53, $P = 0.001$) respectively. The MS decreased significantly in treated group after 2 months compared to 1 month; $P = 0.000$ as seen in Table 1.

Morphometric computerized image analysis

Regarding cell count, there was a statistically significant difference between the studied groups with

Table 1 Comparison between the studied groups regarding Mankin Score

Groups	Group I	Group II		Group III		Test value‡	*P*-value	Sig	
		a	b	a	b				
Mankin's Score mean ± SD	0.00 ± 0.00	10.75 ± 0.50	8.50 ± 0.58	2.50 ± 0.53	0.50 ± 0.53	37.493	0.000	HS	
Post Hoc analysis by Mann Whitney test									
P1	P2	P3	P4	P5	P6	P7	P8	P9	P10
0.000	0.000	0.000	0.000	0.000	0.000	0.000	0.000	0.000	0.008

Group I: healthy control, Group II: untreated, Group III: SVF treated, a: at 1 month, b: at 2 months, *P*-value < 0.01: highly significant (HS), ‡: Kruskal Wallis test, Vs: versus, P1: Group IIa Vs Group IIb, P2: Group IIa Vs Group IIIa, P3: Group IIa Vs Group IIIb, P4: Group IIa Vs Group I, P5: Group IIb Vs Group IIIa, P6: Group IIb Vs Group IIIb, P7: Group IIb Vs Group I, P8: Group IIIa Vs Group IIIb, P9: Group IIa Vs Group I, P10: Group IIIb Vs Group I

p-value < 0.001. Group I had the highest cell count (42.86 ± 6.28 cells/ HPF) followed by treated Group III while the lowest count was in untreated Group II. Post hoc analysis showed that group II cell count was significantly less than group III and Group I ($P < 0.001$) both at 1 and 2 months. Cell count was comparable in treatment Group III and group I both at 1 and 2 months, as seen in Table 2.

As regards articular cartilage thickness, there was a statistically significant difference between the studied groups with *p*-value < 0.001; the highest thickness was found in Group I followed by Group III. The lowest cartilage thickness was found in Group II. Also, post hoc analysis showed statistically significant difference at 1 and 2 months between untreated Group II and both healthy and treated Group III ($P = 0.000$, $P = 0.016$) and ($P = 0.019$, $P = 0.009$) respectively seen in Table 2.

As regards optical density (OD) of articular cartilage in sections of knee joint stained with Safranin- O; the highest density was in Group I with a mean ± SD of 94.66 ± 4.68 followed by Group III at 1 and 2 months (81.77 ± 3.09, 83.26 ± 5.47 respectively) and the least density was in untreated Group II (67.32 ± 4.25, 71.60 ± 3.49 respectively) with highly significant statistical difference between groups ($P < 0.001$). Post hoc analysis showed that OD in Group II at 1 and 2 months respectively was significantly less than the treated Groups III and healthy controls ($P < 0.001$) as seen in Table 2.

Discussion

Regenerative medicine based on stem cells in adipose tissue is considered a promising treatment modality for many orthopedic problems [19]. This current study was designed to find the possible regenerative power of adipose derived SVF in OA through testing its efficacy for treatment of induced OA in rats.

In our experiment, SVF cells were negative for hematopoietic markers (CD34 and CD45) and positive for mesenchymal stem cells markers (CD44) by flow-cytometry consistent with previous studies [20–23].

It is worth noting that in the present work, quantitative PCR helped detect SRY- gene specific for Y chromosome in a section of the knee from the treated female rats, ensuring incorporation of cells of SVF origin obtained from the donor male rat 2 weeks after injection with SVF. Zhang et al., used SRY-gene for tracing origin of cells in repaired cartilage defect in pigs by in situ implantation of cartilage allograft [16].

Histo-pathology is the gold standard for the assessment of OA changes in animal models [24]. In this work, histopathological examination of the right knee of the female rats 2 weeks after induction showed the typical changes in cartilage and synovial membrane characteristic of collagenase induced OA as in previous studies [14, 25]. These changes are quite similar to those that happen in human OA [14].

In the present work, at 1 month after OA induction, the untreated Group II showed continuous progressive OA changes that persisted at 2 months with no evidence of regeneration. This is in accordance with previous studies that showed surface small fissures, superficial erosions of the articular cartilage surface and chondrocytes clusters 4 weeks after induction [25, 26]. In their work, Adães et al. [25], observed changes of established OA at week 6.

On the other hand, the SVF treated group III at 1 month, showed smooth articular surface with no irregularities and abundant chondrocyte cells with viable nuclei, although disorganized. This was similar to the work of Desando et al. [26], in a rabbit OA model, where treatment with SVF contributed to enhancing the tissue quality after 1 month, though there was no statistical evidence. At 2 months in our study, the SVF treated group's histopathological findings were almost comparable to healthy control group and showed evidence of regeneration with smooth surface of cartilage, cells re-organized in zones, near normal staining of matrix and tidemark well defined.

Table 2 Comparison between the studied groups regarding computerized morphometric analysis

	Group I	Group II		Group III		Test value•	*P*-value	Sig		
		a	b	a	b					
Chondrocyte cell count	42.86 ± 6.28	20.75 ± 1.71	26.25 ± 3.30	42.10 ± 3.18	39.40 ± 2.88	71.262	0.000	HS		
Articular cartilage thickness	99.00 ± 10.20	73.85 ± 12.52	56.05 ± 8.61	87.34 ± 9.99	76.36 ± 6.38	27.044	0.000	HS		
OD Hx&E	87.16 ± 4.01	71.63 ± 3.58	71.10 ± 2.28	81.35 ± 3.18	80.48 ± 2.05	48.769	0.000	HS		
OD Safranin	94.66 ± 4.68	67.32 ± 4.25	71.60 ± 3.49	81.77 ± 3.09	83.26 ± 5.47	62.713	0.000	HS		
Post Hoc analysis by LSD										
	P1	P2	P3	P4	P5	P6	P7	P8	P9	P10
Chondrocyte cell count cells/HPF	0.000	0.000	0.000	0.000	0.000	0.000	0.000	0.062	0.737	0.131
Articular cartilage thickness	0.002	0.016	0.579	0.000	0.000	0.000	0.000	0.009	0.019	0.000
OD Hx&E	0.678	0.000	0.000	0.000	0.000	0.000	0.000	0.477	0.002	0.000
OD Safranin	0.024	0.000	0.000	0.000	0.000	0.000	0.000	0.463	0.000	0.000

Group I: healthy control, Group II: untreated, Group III: SVF treated, a: at 1 month, b: at 2 months, *P*-value < 0.01: highly significant (HS), •: One Way ANOVA test, cells/HPF: number of cells/High Power Field, OD: optical density, Hx&E: hematoxylin and eosin, Fisher's Least Significant Difference test: LSD, Vs: versus, P1: Group IIa Vs Group IIb, P2: Group IIa Vs Group IIIa, P3: Group IIa Vs Group IIIb, P4: Group IIa Vs Group I, P5: Group IIb Vs Group IIIa, P6: Group IIb Vs Group IIIb, P7: Group IIb Vs Group I, P8: Group IIIa Vs Group IIIb, P9: Group IIIa Vs Group I, P10: Group IIIb Vs Group I

According to a study by Van lent et al. [27], inflammatory cytokines are highest within the synovium during the first 7 days post OA induction. In the present work, the synovial lining appeared comparable to normal healthy controls after treatment. Both at 1 and 2 months, it showed less inflammatory cells in comparison to untreated group. This could indicate SVF has an anti-inflammatory role. According to a previous study by Blom et al., [28] in collagenase induced OA, thickened synovial lining observed comprised mainly activated macrophages involved in mediating cartilage destruction. Previous work revealed MSC in ADSCs and SVF had anti-inflammatory properties [29, 30]. Moreover SVF, through its paracrine effect, could modulate inflammation and initiate regeneration in joints [31].

In the current study, sections in knee joint stained with safranin-O stain helped demonstrate the proteoglycan content in the cartilage. Proteoglycans, such as aggrecans, are considered a major component in cartilage. Continuous loss of safranin-O stain is an indication of proteoglycan loss, hence, loss of cartilage [32]. There was marked decrease in staining of superficial and deep layer of cartilage observed in Group II compared to group III and confirmed by quantifying OD by computerized image analysis. The OD in slides stained with safranin was significantly decreased in untreated compared to treated groups both at 1 and 2 months. The study by Rothrauff et al., [33] in a goat model of meniscal injury treated with SVF showed more proteoglycan content of cartilage in treated group compared to untreated ones. Similarly, Desando et al., [26] showed several areas of the Safranin O positive cell clones and increased content of the extra-cellular matrix (ECM) proteoglycan after 1 month of SVF treatment. These previous studies are in accordance to our findings that SVF treated groups showed increased proteoglycan content in ECM.

It has been previously reported that combined therapy of SVF with PRP in rat model [34] or hyaluronic acid in sheep [35] was effective in cartilage regeneration through inducing neo-cartilage formation and marked articular ulcer alleviation which proves the potential value of SVF in regeneration of cartilage and supports the findings in our study.

In the present work, the significant difference observed between untreated and treated groups regarding modified MS both at 1 month and 2 months denotes the decreased progression of OA and cartilage degeneration in the SVF treated group [17]. Moreover, there was a significantly reduced articular cartilage thickness, decreased cell count and drop in matrix OD in the untreated group compared to the SVF treated group both at 1 and 2 months quantified by computerized image analysis. All these findings support the regenerative role of SVF in OA as observed in previous studies [26, 30].

Thus, our study, together with previous studies support the therapeutic role of intra-articular SVF in OA. Although early studies in humans with radiologic follow up reported the beneficial effect of SVF therapy in Knee OA [8, 36], still its safety, efficacy, in addition to its possible role in reversing the degenerative changes with respect to degree of severity is still debatable and under study.

Limitations of the study and future research

In this work, we had the advantage of working on small animal models, making it easier to observe histopathological changes after short and longer follow-up periods of treatment by SVF. Although beneficial prolonged regenerative effect has been noticed with single injection of SVF, future work should focus on more frequent injections or combined treatment. Furthermore, quantitative monitoring of articular cartilage regeneration by ultrasound or magnetic resonance imaging in patients with different degrees of Knee OA treated with SVF could further improve our knowledge regarding its efficacy.

Conclusion

Treatment with adipose-derived SVF decreased the development of degenerative changes at early stages of induced OA in rats and later it promoted regeneration with preserved cartilage thickness, cellular count and increased proteoglycan content rendering it a potential regenerative therapy for Knee OA.

Abbreviations

ADSCs	Adipose-derived stem cells
CD	Cluster of differentiation
ECM	Extra-cellular matrix (ECM)
Hx &E	Hematoxylin and Eosin.
MS	MANKIN-modified score
MSCs	Mesenchymal stem cells
OA	osteoarthritis
OD	optical density
PBS	phosphate buffer saline
SRY	sex-determining region of the Y chromosome
SVF	Stromal vascular fraction

Acknowledgements

The authors would like to express their gratitude to Awatef Mohamed (Veterinary Fellow of Biochemistry) and Osama M Abo Naga (Lab Manager at Stem Cell Research Unit, Histology and Cell Biology Department) without whom this work would not have been accomplished.

Authors' contributions

Prof MG contributed to the idea, study design, and editing of the manuscript. Prof MO contributed to the idea, study design, and editing of the manuscript. Dr SA carried out practical work, handled the categorization of rats into different groups, carrying out induction and treatment, data collection, interpretation and wrote the manuscript. Assist Prof AA contributed to the study design, stromal vascular fraction preparation, histopathology slides reading and preparation, morphometric analysis, data interpretation and manuscript editing. Assist Prof DF contributed to study design and follow up of practical

work; analyzed and interpreted the data; wrote and edited the manuscript. All authors have read and approved the manuscript, and all authors have contributed significantly and are in agreement with the content of the manuscript.

Authors' information
This experimental study was done in the setting of Physical Medicine, Rheumatology and Rehabilitation Department in collaboration with Stem cell research unit in Histology department and Medical Ain Shams Research Institution (MASRI), Faculty of medicine, Ain Shams University.

Funding
This study has had no funding from any resource.

Availability of data and materials
The datasets used and/or analyzed during the current study are available from the corresponding author on reasonable request.

Declarations

Ethics approval and consent to participate
This experimental study was done in the setting of Physical Medicine, Rheumatology and Rehabilitation Department in collaboration with Stem cell research unit in histology department and Medical Ain Shams Research Institution (MASRI), Faculty of medicine, Ain Shams University. In the period from 2019 to 2020. All animal handling, procedures, and sacrifices were approved by Ain Shams University Ethical Committee, approval reference number: MS413/2019 and have therefore been performed in accordance with the ethical standards laid down in the 1964 Declaration of Helsinki and its later amendments.
This work has not been published or submitted for publication elsewhere. Only a preliminary version of abstract has been published in the setting of the 42nd Annual International Ain Shams Medical Congress https://doi.org/10.1093/qjmed/hcad069.685 [37].

Consent for publication
Not applicable.

Competing interests
The authors declare that they have no competing interests.

Received: 30 October 2023 Accepted: 13 March 2024
Published online: 25 March 2024

References

1. Hawker GA, King LK (2022) The Burden of Osteoarthritis in Older Adults. Clin Geriatr Med 38(2):181–192. https://doi.org/10.1016/j.cger.2021.11.005
2. Freitag J, Kenihan M (2018) Mesenchymal Stem Cell Therapy in Osteoarthritis and Regenerative Medicine. Curr Sports Med Rep 17(12):441–443. https://doi.org/10.1249/JSR.0000000000000541
3. Zhang R, Ma J, Han J, Zhang W, Ma J (2019) Mesenchymal stem cell related therapies for cartilage lesions and osteoarthritis. Am J Transl Res 11(10):6275–6289 (PMID: 31737182; PMCID: PMC6834499)
4. Kim SA, Sur YJ, Cho ML, Go EJ, Kim YH, Shetty AA et al (2020) Atelocollagen promotes chondrogenic differentiation of human adipose-derived mesenchymal stem cells. Sci Rep 10:10678. https://doi.org/10.1038/s41598-020-67836-3
5. Chahal J, Gómez-Aristizábal A, Shestopaloff K, Bhatt S, Chaboureau A, Fazio A et al (2019) Bone Marrow Mesenchymal Stromal Cell Treatment in Patients with Osteoarthritis Results in Overall Improvement in Pain and Symptoms and Reduces Synovial Inflammation. Stem Cells Transl Med 8:746–757. https://doi.org/10.1002/sctm.18-0183.PMID:30964245;PMCID:PMC6646697
6. Kamel NS, Arafa MM, Nadim A, Amer H, Amin IR, Samir N et al (2014) Effect of intra-articular injection of mesenchymal stem cells in cartilage repair in experimental animals. The Egyptian Rheumatologist 36(4):179–186. https://doi.org/10.1016/j.ejr.2014.03.001
7. Emadedin M, Labibzadeh N, Liastani MG, Karimi A, Jaroughi N, Bolurieh T et al (2018) Intra-articular implantation of autologous bone marrow-derived mesenchymal stromal cells to treat knee osteoarthritis: a randomized, triple-blind, placebo-controlled phase 1/2 clinical trial. Cytotherapy 20(10):1238–1246. https://doi.org/10.1016/j.jcyt.2018.08.005
8. Bolia IK, Bougioukli S, Hill WJ, Trasolini NA, Petrigaliano FA, Lieberman JR et al (2022) Clinical Efficacy of Bone Marrow Aspirate Concentrate Versus Stromal Vascular Fraction Injection in Patients With Knee Osteoarthritis: A Systematic Review and Meta-analysis. Am J Sports Med 50(5):1451–1461. https://doi.org/10.1177/03635465211014500
9. Chu DT, Nguyen Thi Phuong T, Tien NLB, Tran DK, Minh LB, Thanh VV et al (2019) Adipose Tissue Stem Cells for Therapy: An Update on the Progress of Isolation, Culture, Storage, and Clinical Application. J Clin Med 8(7):917. https://doi.org/10.3390/jcm8070917
10. Gentile P, Scioli MG, Bielli A, Orlandi A, Cervelli V (2017) Concise Review: The Use of Adipose-Derived Stromal Vascular Fraction Cells and Platelet Rich Plasma in Regenerative Plastic Surgery. Stem Cells 35:117–134. https://doi.org/10.1002/stem.2498
11. Bora P, Majumdar AS (2017) Adipose tissue-derived stromal vascular fraction in regenerative medicine: a brief review on biology and translation. Stem Cell Res Ther 8:145. https://doi.org/10.1186/s13287-017-0598-y
12. Biazzo A, D'Ambrosi R, Masia F, Izzo V, Verde F (2020) Autologous adipose stem cell therapy for knee osteoarthritis: where are we now. The Physician and Sports medicine 48(4):392–399. https://doi.org/10.1080/00913847.2020.1758001
13. Song Y, Du H, Dai C, Zhang L, Li S, Hunter DJ et al (2018) Human adipose-derived mesenchymal stem cells for osteoarthritis: a pilot study with long-term follow-up and repeated injections. Regen Med 13(3):295–307. https://doi.org/10.2217/rme-2017-0152. Epub 2018 Feb 8 PMID: 29417902.
14. Kikuchi T, Sakuta T, Yamaguchi T (1998) Intra-articular injection of collagenase induces experimental osteoarthritis in mature rabbits. Osteoarthritis Cartilage 6:177–186
15. Van Pham P, Hong-Thien Bui K, Quoc Ngo D, Tan Khuat L, Kim Phan N (2013) Transplantation of Nonexpanded Adipose Stromal Vascular Fraction and Platelet-Rich Plasma for Articular Cartilage Injury Treatment in Mice Model. Journal of medical engineering 832396. https://doi.org/10.1155/2013/832396
16. Zhang C, Ao Y, Cao J, Yang L, Duan X (2020) Donor Cell Fate in Particulated Juvenile Allograft Cartilage for the Repair of Articular Cartilage Defects. Am J Sports Med 48(13):3224–3232. https://doi.org/10.1177/0363546520958700
17. Mankin HJ, Dorfman H, Lippiello L, Zarins A (1971) Biochemical and metabolic abnormalities in articular cartilage from osteo-arthritic human hips. II. Correlation of morphology with biochemical and metabolic data. J Bone Joint Surg Am 53:523–537
18. Ma CH, Lv Q, Yu YX, Zhang Y, Kong D, Niu KR et al (2015) Protective effects of tumor necrosis factor-α blockade by adalimumab on articular cartilage and subchondral bone in a rat model of osteoarthritis. Braz J Med Biol Res 48(10):863–870. https://doi.org/10.1590/1414-431X20154407
19. Pak J, Lee JH, Park KS, Park M, Kang LW, Lee SH (2017) Current use of autologous adipose tissue-derived stromal vascular fraction cells for orthopedic applications. J Biomed Sci 24(1):1–2
20. Rebelatto CK, Aguiar AM, Moretao MP, Senegaglia AC, Hansen P, Barchiki F et al (2008) Dissimilar differentiation of mesenchymal stem cells from bone marrow, umbilical cord blood, and adipose tissue. Exp Biol Med 233(7):901–913
21. Blande I, Bassaneze V, Lavini-Ramos C, Fae K, Kalil J, Miyakawa A et al (2009) Adipose tissue mesenchymal stem cell expansion in animal serum-free medium supplemented with autologous human platelet lysate. Transfusion 49(12):2680–2685
22. Shih DT, Chen JC, Chen WY, Kuo YP, Su CY, Burnouf T (2011) Expansion of adipose tissue mesenchymal stromal progenitors in serum-free medium supplemented with virally inactivated allogeneic human platelet lysate. Transfusion 51(4):770–778
23. Latief N, Raza FA, Bhatti FUR, Tarar MN, Khan SN, Riazuddin S (2016) Adipose stem cells differentiated chondrocytes regenerate damaged cartilage in rat model of osteoarthritis. Cell Biol Int 40(5):579–588
24. Rutgers M, van Pelt MJP, Dhert WJA, Creemers LB, Saris DBF (2020) Evaluation of histological scoring systems for tissue-engineered, repaired and osteoarthritic cartilage. Osteoarthritis Cartilage 18(1):12–23

25. Adães S, Mendonça M, Santos TN, Castro-Lopes JM, Ferreira-Gomes J, Neto FL (2014) Intra-articular injection of collagenase in the knee of rats as an alternative model to study nociception associated with osteoarthritis. Arthritis Res Ther 16(1):10
26. Desando G, Bartolotti I, Martini L, Giavaresi G, Aldini N, Fini M et al (2019) Regenerative Features of Adipose Tissue for Osteoarthritis Treatment in a Rabbit Model: Enzymatic Digestion Versus Mechanical Disruption, international journal of molecular sciences Int. J Mol Sci 20:2636
27. Van Lent PL, Blom AB, van der Kraan P, Holthuysen AE, Vitters E, van Rooijen N et al (2004) Crucial role of synovial lining macrophages in the promotion of transforming growth factor – mediated osteophyte formation. Arthritis Rheum 50:103–111
28. Blom AB, van Lent PL, Libregts S, Holthuysen AE, van der Kraan PM, van Rooijen N et al (2007) Crucial role of macrophages in matrix metalloproteinase–mediated cartilage destruction during experimental osteoarthritis: involvement of matrix metalloproteinase 3. Arthritis Rheum 56:147–157
29. Dooley LM, Abdalmula A, Washington EA, Kaufman C, Tudor EM, Ghosh P et al (2015) Effect of mesenchymal precursor cells on the systemic inflammatory response and endothelial dysfunction in an ovine model of collagen-induced arthritis. PLoS ONE 10(5):e0124144. https://doi.org/10.1371/journal.pone.0124144. PMID:25950840;PMCID:PMC4423911
30. Yang WT, Ke CY, Yeh KT, Huang SG, Lin ZY, Wu WT et al (2022) Stromal-vascular fraction and adipose-derived stem cell therapies improve cartilage regeneration in osteoarthritis-induced rats. Sci Rep 12(1):2828. https://doi.org/10.1038/s41598-022-06892-3. (PMID:35181731;PMCID:PMC8857326)
31. Vargel İ, Tuncel A, Baysal N, Hartuç-Çevik İ, Korkusuz F (2022) Autologous Adipose-Derived Tissue Stromal Vascular Fraction (AD-tSVF) for Knee Osteoarthritis. Int J Mol Sci 23(21):13517. https://doi.org/10.3390/ijms232113517
32. Satkunananthan PB, Anderson MJ, De Jesus NM, Haudenschild DR, Ripplinger CM, Christiansen BA (2014) In vivo fluorescence reflectance imaging of protease activity in a mouse model of post-traumatic osteoarthritis. Osteoarthritis Cartilage 22(10):1461–1469
33. Rothrauff BB, Sasaki H, Kihara S, Overholt KJ, Gottardi R, Lin H et al (2019) Point-of-Care Procedure for Enhancement of Meniscal Healing in a Goat Model Utilizing Infrapatellar Fat Pad-Derived Stromal Vascular Fraction Cells Seeded in Photocrosslinkable Hydrogel. Am J Sports Med 2019:036354651988046
34. Van Pham P, Hong-Thien Bui K, Quoc Ngo D, Tan Khuat L, Kim Phan N (2013) Transplantation of nonexpanded adipose stromal vascular fraction and platelet-rich plasma for articular cartilage injury treatment in mice model. J Med Eng 2013:832396. https://doi.org/10.1155/2013/832396
35. Lv X, He J, Zhang X, Luo X, He N, Sun Z et al (2018) Comparative Efficacy of Autologous Stromal Vascular Fraction and Autologous Adipose-Derived Mesenchymal Stem Cells Combined With Hyaluronic Acid for the Treatment of Sheep Osteoarthritis. Cell Transplant 27(7):1111–1125. https://doi.org/10.1177/0963689718773333
36. Yang Y, Lan Z, Yan J, Tang Z, Zhou L, Jin D et al (2023) Effect of intra-knee injection of autologous adipose stem cells or mesenchymal vascular components on short-term outcomes in patients with knee osteoarthritis: an updated meta-analysis of randomized controlled trials. Arthritis Res Ther 25(1):147. https://doi.org/10.1186/s13075-023-03134-3. PMID:37563715;PMCID:PMC10413774
37. Moussa SA, Zaki MG, Mohamed MO, Abo Zeid AA, Farrag D (2023) Adipose-Derived Stromal Vascular Fraction in Treatment of Osteoarthritis: Experimental Study. QJM: An International Journal of Medicine 116(1)1, hcad069.685, https://doi.org/10.1093/qjmed/hcad069.685

Publisher's Note