Elwakil *et al.*
Egyptian Rheumatology and Rehabilitation (2024) 51:3
https://doi.org/10.1186/s43166-023-00235-4

Egyptian Rheumatology and Rehabilitation

RESEARCH

Open Access

Ulnar nerve involvement at the wrist in idiopathic mild to moderate carpal tunnel syndrome: electrophysiological and ultrasonographic study

Walaa Elwakil[1*], Hussein Elmoghazy Sultan[1], Marwa Hassan[1], Mohamed Elshafei[2] and Esraa Hammad[1]

Abstract

Background Carpal tunnel syndrome (CTS) is a common entrapment neuropathy. It is clinically presented by nocturnal pain, paresthesia, and weakness in the distribution of the median nerve. However, extra-median symptoms may develop in some patients, particularly those with mild to moderate CTS. This raised the assumption of possible concomitant ulnar nerve entrapment at the wrist, or Guyon's canal syndrome (GCS). The aim of this study is to evaluate functional and structural changes that may take place in the ulnar nerve at the wrist in those patients.

Methods This is a retrospective case–control study that included forty patients with mild to moderate CTS and 40 matched subjects as a control group. Electrophysiological evaluation was done for all the participants in addition to measuring median and ulnar nerves sonographic parameters in the form of median cross-sectional area (m-CSA) at the level of pisiform bone, median flattening ratio (m-FR), median swelling ratio (m-SR), the difference between m-CSA at the inlet of the carpal tunnel and m-CSA at the distal third of the pronator quadratus (Δ m-CSA), as well as the ulnar cross-sectional area (u-CSA) at the same level.

Results The u-CSA was larger in the patients relative to the control (5.23 ± 1.21 mm^2 versus 3.28 ± 0.64 mm^2). It did not correlate with m-CSA. However, a statistically significant correlation was demonstrated between u-CSA and median motor conduction parameters ($P \leq 0.001$).

Conclusion Although patients with mild to moderate idiopathic CTS may have normal electrophysiological parameters of the ulnar nerve, ultrasonographic evaluation is valuable to detect early ulnar nerve structural changes, which appear to be likely due to concomitant distal ulnar nerve entrapment at the Guyon's canal, which may contribute to the development of extra-median symptoms in those patients.

Keywords Median nerve, Ulnar nerve, Carpal tunnel syndrome, Guyon canal, Sonography, Extra-median symptoms

Background

Entrapment neuropathies of the upper extremities are the most common peripheral neuropathies. They are caused by compression or traction of the peripheral nerves as they travel through a narrow anatomical site. The etiology of entrapment neuropathies is not fully understood. The multifactorial etiology may contribute to the heterogeneity of patients' symptoms [1].

*Correspondence:
Walaa Elwakil
walaa.ali@alexmed.edu.eg
[1] Department of Rheumatology, Rehabilitation and Physical Medicine, Alexandria University, Alexandria, Egypt
[2] Department of Diagnostic and Interventional Radiology, Alexandria University, Alexandria, Egypt

The pathophysiological changes that take place in entrapment neuropathies due to chronic compression include intraneural ischemia which compromises the blood-nerve interface resulting in nerve edema manifested as enlargement of the nerve segment distal to the site of compression. Eventually, extra-neural and intraneural fibrotic changes occur due to prolonged edema. Demyelination is the hallmark of entrapment neuropathies with subsequent axonal degeneration due to prolonged ischemia. Additionally, central sensitization and structural changes in the somatosensory cortex have been reported in patients with severe prolonged entrapment neuropathies which may contribute to widespread hypersensitivity and altered pain modulation [2]. It is debatable whether central changes are dependent on peripheral causes or can drive symptoms on their own.

Carpal tunnel syndrome (CTS) is the most common entrapment neuropathy of the upper extremity. CTS is caused by compression of the median nerve under the transverse carpal ligament. The classical symptoms of CTS are nocturnal pain, paresthesia, weakness, and loss of function in the distribution of the median nerve [3]. However, extra-median symptoms involving the medial hand and one and a half fingers supplied by the ulnar nerve were frequently noticed, raising the assumption of possible concomitant ulnar nerve entrapment at the wrist or Guyon's canal syndrome (GCS) [4].

Several theories were hypothesized to explain these whole-hand symptoms; one of them was increased central sensitization [5, 6]. Another theory was built on the assumption of possible structural or functional changes that may take place in the ulnar nerve in patients with CTS due to the close contiguity between the carpal tunnel and Guyon canal (GC) at the wrist [7]. The volar carpal ligament constitutes the floor of the GC and the roof of the carpal tunnel. Therefore, increased pressure in the carpal tunnel may affect the ulnar nerve at the wrist level, and this may explain the extra-median spread of symptoms [8].

There is still controversy regarding ulnar nerve abnormalities at the wrist in idiopathic CTS and their possible role in the development of extra-median symptoms; therefore, the aim of the study was to assess possible early functional and structural changes that might take place in the ulnar nerve in patients with idiopathic mild to moderate carpal tunnel syndrome before central changes take place.

Subjects and methods

This retrospective case–control study included 40 patients with CTS diagnosed according to the criteria of the American Association of Electrodiagnostic Medicine (AAEM) [9], and only those with CTS of a mild to moderate degree according to the scale of Padua et al. [10] were included in the study. Forty healthy subjects of matched age, sex, and body mass index constituted the control group. The study was approved by the local ethical committee, and written consent was signed by all the participants.

A detailed history was taken, and a careful clinical examination was performed to exclude the presence of other diseases that could be related to CTS. The exclusion criteria were (1) history of any potentially confounding conditions such as neurologic, orthopedic, rheumatologic, or endocrine diseases, renal failure, diabetes mellitus, and pregnancy; (2) previous surgery for CTS; (3) proximal median or ulnar nerve affection; (4) history of a previous injury or fracture to the upper limb; (5) peripheral neuropathy; (6) cervical radiculopathy; (7) edema of the upper limb; (8) CTS related to occupational injuries; and (9) patients previously treated with local corticosteroid injection. Additionally, the asymptomatic contralateral upper limb was not included as a control due to the possibility of subclinical CTS.

Patient assessment

Hand symptoms were classified according to a self-administered hand symptoms diagram regarding the distribution of sensory symptoms derived from the original diagram of Katz et al. [11]. Patients were asked to indicate the distribution of their paresthesia by marking areas of discomfort on the hand diagram. They were not asked to distinguish in the diagram between numbness and tingling. The diagram was graded into median (MED) and extra-median (EXTRAMED) patterns.

Neurophysiological examination

The neurophysiological evaluation was done for all the participants by an experienced physiatrist, using Viking Quest electrodiagnostic apparatus (Nicolet ViaSys Healthcare, USA). Nerve conduction studies were performed using AAEM-recommended nerve conduction techniques [12]. The following nerves were studied:

- Antidromic sensory conduction studies for the median and ulnar nerves were recorded from the 2nd and 5th digits, respectively, with a fixed distance of 14 cm. The following parameters were recorded: peak sensory latency (PSL), onset to peak amplitude (OPA) of sensory nerve action potentials (SNAP), and sensory conduction velocity.
- Sensory conduction study of the superficial radial and dorsal ulnar cutaneous branch of the ulnar nerve.
- Motor conduction studies of the median nerve stimulating the median nerve at the wrist, recording from abductor pollicis brevis muscle (APB), and motor

conduction studies of the ulnar nerve stimulating the ulnar nerve at the medial wrist adjacent to the flexor carpi ulnaris tendon, recording from abductor digiti-minimi muscle (ADM) as well as first dorsal interosseus muscle (DI). The distance between the stimulating electrode and the active recording electrode was 8 cm. The following parameters were recorded: distal motor latency (DML), compound muscle action potential (CMAP) amplitude, and motor conduction velocity at the forearm segment (MCV). Measuring u-MCV at the elbow segment was done to exclude entrapment of the ulnar nerve across the elbow region.

Ultrasonographic examination

The ultrasonographic examination was carried out for all the participants on the same day of electrodiagnostic evaluation using a 12-MHz linear array transducer (GE Logiq S6 Ultrasound System) by a radiologist experienced in neuromuscular ultrasound who was blinded regarding the patients and their electrophysiological evaluation. The sonographic examination of the median and ulnar nerves was done with the upper limb placed in the supine position and palm up, at the distal wrist crease, with the transducer placed perpendicular to the nerve to obtain a transverse view. The probe was applied cautiously to avoid additional pressure on the nerves. The following parameters were measured:

- Median nerve cross-sectional area (m-CSA) and ulnar nerve cross-sectional area (u-CSA) at the pisiform level. The area was calculated using the continuous trace method by outlining the perimeter just inside the hyperechoic epineurium [13–15]. The CSA of the bifid median nerve was calculated by adding the individual CSAs of its two components.
- Median nerve flattening ratio (m-FR), which is defined as the ratio of the transverse diameter to the anteroposterior diameter of the median nerve at the level of the hook of the hamate [16].
- Median nerve swelling ratio (m-SR): m-CSA was measured 4 cm proximal to the distal end of the radius. The m-SR was calculated as m-CSA at the pisiform/m-CSA 4 cm proximal to the distal end of the radius [17].
- The difference between m-CSA at the inlet of the carpal tunnel and m-CSA at the distal third of the pronator quadratus (Δ m-CSA) was calculated by subtracting the cross-sectional area at the level of the pronator quadratus from the cross-sectional area at the carpal tunnel inlet, reflecting the swelling of the median nerve distally [18].

Statistical analysis

Data were fed to the computer and analyzed using IBM SPSS software package version 20.0. (Armonk, NY: IBM Corp.). The sample size was estimated using the PASS Version 20 program. A minimal total hypothesized sample size of 80 eligible participants (40 per group) was needed to assess the possibility of distal ulnar involvement with carpal tunnel syndrome of mild to moderate degree by electrodiagnostic and ultrasonographic evaluation, taking into consideration a 95% confidence level and 80% power using the chi-square test.

Qualitative data were described using numbers and percentages. The Shapiro–Wilk test was used to verify the normality of the distribution. Quantitative data were described using range (minimum and maximum), mean, standard deviation, median, and interquartile range (IQR). The chi-square test was used for categorical variables to compare different groups. Student *t*-test was used for normally distributed quantitative variables to compare the two studied groups, while the Mann–Whitney test was used to compare the studied groups for abnormally distributed quantitative variables. Pearson coefficient test was used to correlate normally distributed quantitative variables. The Bonferroni test was used for statistical correction of multiple tests.

Results

This study included 40 right-handed female patients with clinical and electrophysiological features suggestive of carpal tunnel syndrome. The mean duration of their hand symptoms was 2.23 ± 0.6 years. Forty right-handed asymptomatic females of comparable age, weight, height, and body mass index constituted the control group. The symptomless contralateral side of some patients was not considered a control due to the possibility of subclinical CTS. 95% of the patients as well as the control group were housewives (Table 1). Among the patients, 72.5% ($n=29$) had right CTS, while left CTS was reported in 37.5% ($n=11$). According to the scale of Padua et al., 9 patients (22.5%) had mild CTS and 31 patients (77.5%) had CTS of moderate degree. Regarding the control group, evaluation was done on 40 hands (29 right hands and 11 left hands).

Clinically, paresthesia of the hand was the major complaint of all the patients. According to the hand diagram of Katz et al., all the patients had hand paresthesia in the distribution of the median nerve, while extra-median or whole-hand paresthesia was observed in 55% ($n=22$) of them. A motor deficit involving the thenar muscles (grade 4+ −4 on the Motor Research Council scale) was noted in 70% of the patients ($n=28$), while no motor

Table 1 Comparison between the two studied groups according to occupation, age, and anthropometric measurements

	Cases ($n=40$)		Control ($n=40$)		Test of Sig	*p*
	No	%	No	%		
Gender (female)	40	100.0	40	100.0	–	–
Occupation						
Housewife	38	95.0	38	95.0	$\chi^2=0.000$	$^{FE}p=1.000$
Employee	2	5.0	2	5.0		
Age (years)						
Min.–max	27.0–52.0		27.0–53.0		$t=0.518$	0.606
Mean ± SD	38.82 ± 7.80		37.93 ± 7.73			
Median (IQR)	39.0 (33.0–45.0)		35.50 (32.0–44.5)			
Height (cm)						
Min.–max	150.0–170.0		157.0–170.0		$t=0.677$	0 .500
Mean ± SD	160.3 ± 4.27		160.9 ± 3.26			
Median (IQR)	160.0(157.0–163.0)		160.0(158.0–163.0)			
Weight (kg)						
Min.–max	68.0–103.0		70.0–90.0		$t=0.943$	0.348
Mean ± SD	81.35 ± 7.35		79.95 ± 5.84			
Median (IQR)	80.50 (78.5–85.0)		80.0 (75.50–85.0)			
BMI (kg/m^2)						
Min.–max	27.10–36.49		26.10–34.20		$t=1.644$	0.104
Mean ± SD	31.63 ± 2.16		30.61 ± 1.95			
Median (IQR)	32.02 (30.28–33.2)		31.20 (29.40–32.0)			

Bold values indicate statistical significance at $p \leq 0.05$

IQR interquartile range, *SD* standard deviation, *t* Student *t*-test, χ^2 chi-square test, *FE* Fisher exact

affection of the muscles supplied by the ulnar nerve was detected clinically.

An electrophysiological study revealed no statistically significant differences between both groups regarding the motor conduction parameters of the ulnar nerve. However, sensory conduction parameters of the ulnar nerve were significantly abnormal in the patient group compared to the control group (Table 2).

Ultrasonographic evaluation of all the participants revealed a significant enlargement of the m-CSA at the level of the pisiform bone ($p<0.001$) among the patient group. Additionally, m-SR and Δm-CSA were significantly higher in the patient group. Similarly, the u-CSA of the patients was significantly higher than the control group (Table 3). Figure 1 demonstrates axial sonograms at the level of pisiform bone in a case of left CTS of moderate degree.

Although no significant relationship was detected between u-CSA and ulnar electrophysiological parameters nor between u-CSA and m-CSA in the patient group, a statistically significant relationship was demonstrated between u-CSA at the level of the pisiform bone and the motor conduction parameters of the median nerve, where a significant positive correlation was detected between u-CSA and median DML ($p<0.001$), while a significant negative correlation was reported between median CMAP amplitude, median MCV, and u-CSA ($p=0.001$ and $p<0.001$, respectively) (Fig. 2).

Discussion

Considerable debate exists in the literature about the possibility of ulnar nerve involvement at the wrist in idiopathic CTS. Entrapment of the ulnar nerve at the wrist, or Guyon's canal syndrome (GCS), is a relatively uncommon type of peripheral ulnar neuropathy that involves injury to the distal part of the ulnar nerve as it travels across the wrist. The hypothesis of possible structural and functional changes that may take place in the ulnar nerve in conjunction with CTS was based on clinical observations of the disappearance of hand paresthesia in ulnar nerve distribution after carpal tunnel release.

In our study, selected patients had mild to moderate CTS with symptoms duration ranging from 1 to 3 years. Whole-hand paresthesia was perceived in 55% of the patients with no motor deficit in the distribution of the ulnar nerve. This was in concordance with the studies conducted by Kang et al., Yemisci et al., and Mansiz-Kaplan et al., which found that around 50% of the

Table 2 Comparison between the two studied groups according to motor and sensory conduction studies of the ulnar nerve

	Electrophysiological parameters	Cases ($n=40$)	Control ($n=40$)	Test of sig	p
Ulnar motor conduction recorded from ADM	**DML (ms)**				
	Min.–max	1.90–3.60	1.80–3.40	$t=1.887$	0.063
	Median (IQR)	2.70 (2.45–2.85)	2.50 (2.30–2.75)		
	CMAP amplitude (mv)				
	Min.–max	4.10–17.50	5.10–17.90	$t=1.958$	0.054
	Median (IQR)	8.65 (6.4–10.4)	9.55 (7.95–12.75)		
	MCV forearm (m/s)				
	Min.–max	49.0–73.20	47.0–75.70	$t=0.655$	0.514
	Median (IQR)	58.0 (55.0–61.0)	60.45 (57.0–66.0)		
	MCV across elbow (m/s)				
	Min.–max	49.0–65.0	53.0–68.0	$t=0.930$	0.355
	Median (IQR)	52.50 (59.0–61.2)	54.50 (60.0–63.0)		
Ulnar motor conduction recorded from 1st DI	**DML (ms)**				
	Min–max	2.34–4.3	2.2–4.1	t= 1.571	0.174
	Median (IQR)	3.4 (3.1–3.7)	3.3 (2.9–3.5)		
	CMAP amplitude (mv)				
	Min.–max	5.1–16.0	6.2–18.3	$t=1.490$	0.144
	Median (IQR)	10.0 (8.35–12.55)	11.4 (9.2–14.5)		
	MCV forearm (m/s)				
	Min.–max	47.5–82.0	49.7–85.0	$t=1.461$	0.152
	Median (IQR)	57.0 (51.5–65.25)	58.2 (52.4–67.5)		
	MCV across elbow (m/s)				
	Min.–max	47.0–78.4	49.0–80.3	$t=1.169$	0.250
	Median (IQR)	63.5 (56.5–67.1)	64.0 (58.2–68.5)		
Ulnar sensory conduction from digit V	**PSL (ms)**				
	Min.–max	2.5–3.8	2.2–3.4	$t=3.428$	**0.001**
	Median (IQR)	2.9 (2.65–3.1)	2.7 (2.2–3.0)		
	OPA (uV)				
	Min–max	10.0–68.0	17.0–79.80	$U=499.50$	**0.004**
	Median (IQR)	31.5 (21.05–43.1)	40.70 (32.7–63.9)		
	SCV (m/s)				
	Min–max	46.0–72.0	54.0–75.0	$t=4.288$	**< 0.001**
	Median (IQR)	57.0 (50.20–65.50)	60.0 (54.60–70.0)		

Bold values indicate statistical significance at $p \leq 0.004$ (after statistical correction by the Bonferroni test)

1st DI first dorsal interosseous muscle, *DML* distal motor latency, *CMAP* compound muscle action potential, *MCV* motor conduction velocity, *PSL* peak sensory latency, *OPA* onset- peak amplitude, *SCV* sensory conduction velocity, *u* ulnar nerve

IQR inter quartile range, *t* Student *t*-test, *U* Mann–Whitney test

patients with idiopathic CTS had paresthesia involving the whole hand [8, 19, 20].

Many studies were conducted to evaluate functional changes in the ulnar nerve in conjunction with idiopathic CTS. In the current study, the electrophysiological parameters of the ulnar nerve in the patient group were within the normal range; however, sensory conduction parameters of the ulnar nerve were significantly abnormal in the patients relative to the control group. In agreement with our findings, several studies, including one conducted on the same population [19, 21–27], documented significant changes in sensory parameters of ulnar nerve conduction in patients with idiopathic CTS. The most frequent abnormality noted was a slowed u-SCV, followed by a reduction in u-SNAP amplitude. Moreover, two studies found a significant delay in u-SL [22, 28]. On the contrary, other studies did not find any ulnar sensory conduction abnormalities in association with carpal tunnel syndrome [8, 29–31].

Table 3 Comparison between the two studied groups according to ultrasonographic parameters

Ultrasonography	Cases ($n=40$)	Control ($n=40$)	Test of Sig	*P*
m-CSA at pisiform (mm^2)				
Min.–max	9.0–17.0	6.0–9.0	$t=13.805$	**< 0.001**
Median (IQR)	12.0 (11.0–14.0)	7.0 (6.0–8.0)		
Δm-CSA				
Min.–max	1.0–8.0	0.0–2.0	$U=65.0$	**< 0.001**
Median (IQR)	3.0 (2.50–4.0)	1.0 (1.0–1.0)		
m- SR				
Min.–max	1.10–2.70	0.85–1.80	$U=73.0$	**< 0.001**
Median (IQR)	1.50 (1.39–1.56)	1.14 (1.0–1.20)		
m-FR				
Min.–max	2.0–5.70	2.08–4.50	$t=2.389$	0.019
Median (IQR)	3.20 (2.65–3.40)	2.80 (2.50–3.10)		
u-CSA (mm^2)				
Min.–max	3.0–8.0	2.0–4.0	$t=9.017$	**< 0.001**
Median (IQR)	5.0 (4.0–6.0)	3.0 (3.0–4.0)		

Bold values indicate statistical significance at $p \leq 0.004$ (After statistical correlation by Bonferroni test)

CSA cross-sectional area, *m-SR* median swelling ratio, *m-FR* median flattening ratio, *m* median nerve, *u* ulnar nerve, *IQR* interquartile range, *t* Student *t*-test, *U* Mann–Whitney test, *p p* value for comparing between the two studied groups

We did not report significant changes in motor conduction parameters in the patients relative to the controls. Several studies agreed with our findings [8, 24, 28, 30, 32–35]. On the other hand, three studies documented ulnar motor conduction abnormalities mainly in DML and CMAP amplitude relative to the control [19, 25, 36].

The variability in the results may be due to differences in sample size, population characteristics, electrodiagnostic techniques, and the degree of CTS among the recruited patients. Some studies did not exclude patients with diabetes mellitus who may be affected by subtle peripheral neuropathy or a symptomless contralateral hand that may be affected subclinically. Additionally, a lack of selection of matched controls in terms of anthropometric measures and working activities may have an impact on the electrophysiological evaluation. It is worth mentioning that some studies evaluate the ulnar conduction parameters qualitatively in terms of normal versus abnormal rather than quantitative electrophysiological values.

Sonographic evaluation was carried out using a 12-MHz probe. We evaluated the median nerve sonographically by several parameters, such as m-CSA, m-FR, m-SR, as well as Δm-CSA. Except for the m- FR, all ultrasonographic parameters were significantly higher in the patients relative to the control group. Most of the studies that measured the median nerve sonographic parameters in CTS reported the same findings [37–40].

In the current study, normal u-CSA at the level of the pisiform bone was 3.28 ± 0.64 mm^2. Several studies of normal u-CSA values on sonographic evaluation have been reported. In a study conducted on Asian patients, the normal value was 3.6 ± 5.0 mm^2 [41]. Similarly, in the study conducted by Kang et al. on Korean patients [7], u-CSA among the control group was 3.56 ± 0.52 mm^2 (1), while another study from the USA determined the mean normal u-CSA value to be 5.9 ± 1.1 mm^2 [42]. This study is the first to document normal values of distal u-CSA in our

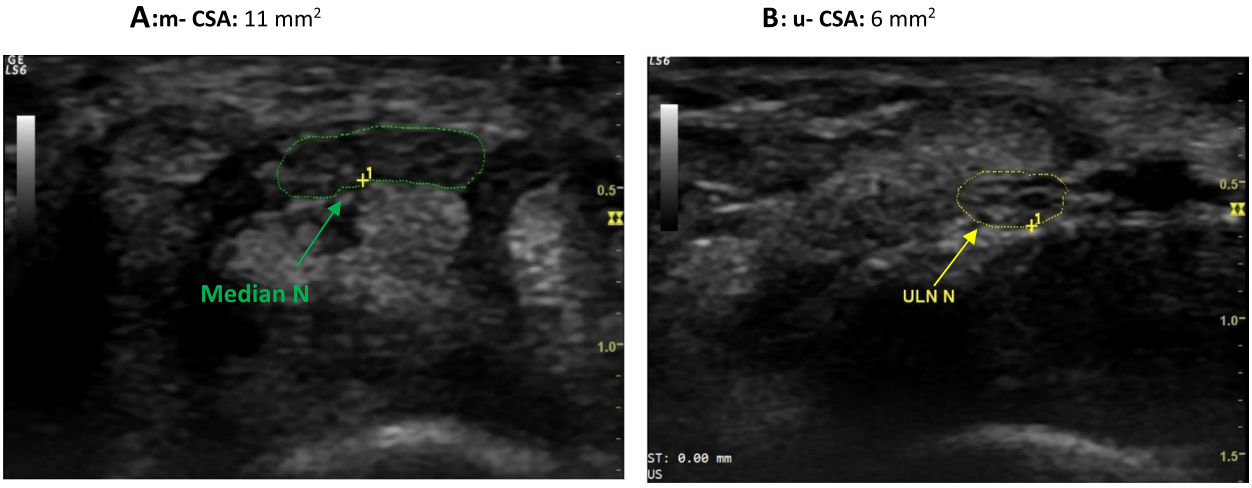

Fig. 1 Axial sonograms at the level of pisiform bone in a case of left CTS of moderate degree. **A** m-CSA: 11 mm^2. **B** u- CSA: 6 mm^2

A

Correlation between median DML (ms) and u-CSA (mm^2)

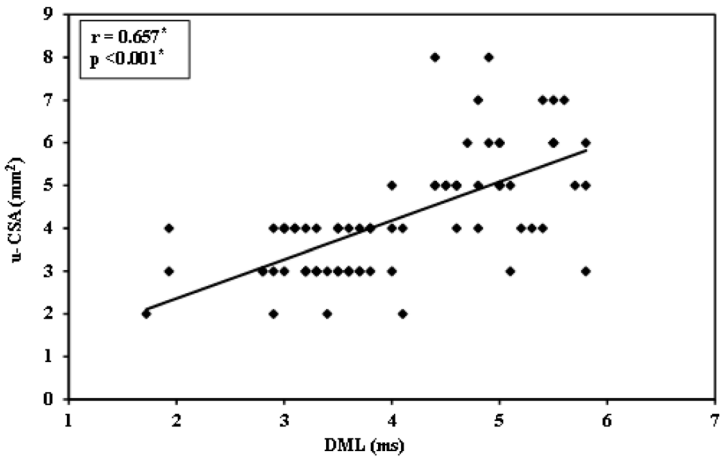

B

Correlation between median CMAP amplitude (mv) and u-CSA (mm^2)

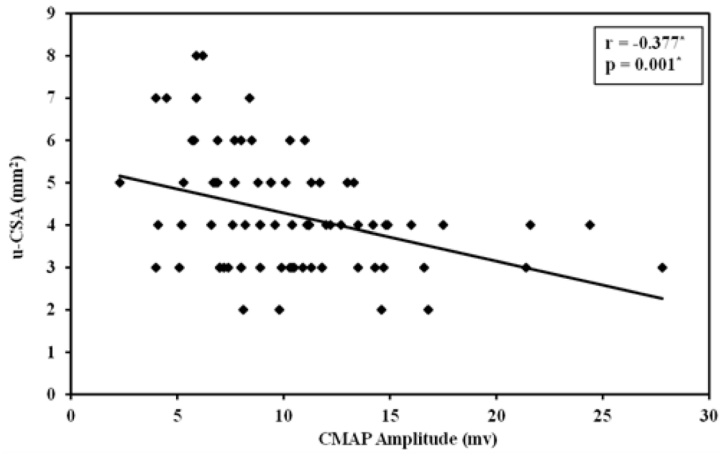

C

Correlation between median MCV (m/s) and u-CSA (mm^2)

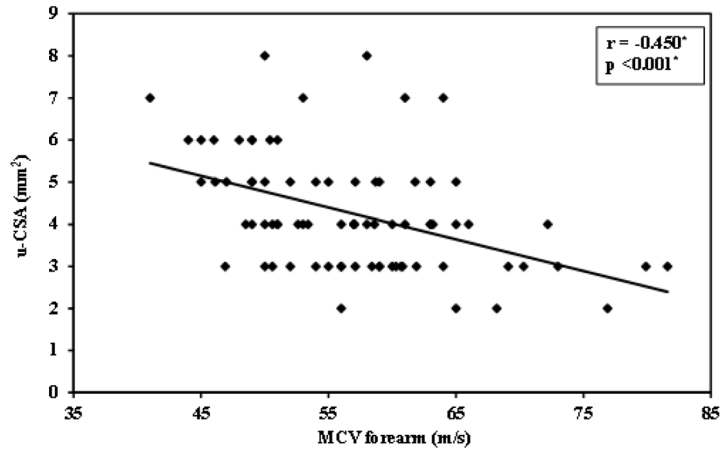

DML: distal motor latency CMAP: compound muscle action potential

MCV: motor conduction velocity u- CSA: ulnar cross-sectional area.

Fig. 2 Correlation between median motor conduction parameters u-CSA. **A** Correlation between median DML (ms) and u-CSA (mm^2). **B** Correlation between median CMAP amplitude (mv) and u-CSA (mm^2). **C** Correlation between median MCV (m/s) and u-CSA (mm^2)

population It seems that differences in age, sex, ethnicity, and anthropometric measures affect the normal u-CSA.

Regarding the ultrasonographic data of the ulnar nerve in conjunction with CTS, a smaller number of studies were published. We demonstrated a significant enlargement of u-CSA relative to the control group, which agreed with the study conducted by Kang et al. [8]. On the contrary, other studies reported a significant reduction in u-CSA relative to the control group [28, 43], and one study by Eom et al. did not show any abnormality in u-CSA [44] in patients with CTS. These conflicting results may reflect the fact that ultrasonography is an operator-dependent diagnostic modality with considerable interobserver variability and different scanning techniques. Moreover, most of these studies used low probe frequencies (< 12 MHz), which warrant caution as the resolution of the image is low, with subsequent less sharp nerve boundaries, making it difficult to accurately measure nerve CSA [45].

It seems reasonable that the long-term increase in pressure in the carpal tunnel and its transmission to the nearby Guyon's canal is likely to result in nerve edema and thus an increase in m-CSA as well as u-CSA. Our explanation is supported by two studies that reported a significant increase in the intraductal pressure of both the carpal and Guyon's tunnels in patients with idiopathic CTS, with a subsequent significant reduction in their pressure after a surgical section of the transverse carpal ligament (TCL) [46, 47]. Moreover, morphological evaluation by magnetic resonance imaging (MRI) demonstrated that Guyon's canal, which had a triangular shape before surgery, turned into an oval or rounded shape after the surgical release of CTS [48, 49]. Unfortunately, no studies were available to demonstrate abnormal sonographic findings of the ulnar nerve secondary to its entrapment in Guyon's canal due to the rarity of such a condition.

Our study has some limitations. First, the study aimed at reporting early changes that take place in the ulnar nerve in conjunction with idiopathic mild to moderate CTS; however, more studies are needed to evaluate ulnar nerve involvement in longstanding severe cases of CTS. Additionally, since the study included only female patients, it will be more informative to conduct future studies on male patients with idiopathic CTS. Moreover, most of the examined hands in our study were dominant hands (72.5%), in the context of the increased cortical presentation of dominant hands. Additional studies on non-dominant hands may give a better insight into possible concomitant changes in the ulnar nerve in patients with idiopathic CTS.

Conclusion

The current study demonstrated functional and structural changes that took place in the ulnar nerve in cases of mild to moderate CTS. Although the electrophysiological parameters of the ulnar nerve were within the normal ranges, we reported statistically significant differences in ulnar sensory electrophysiological parameters in the patients relative to the control group. Additionally, the CSAs of both median and ulnar nerves were larger at the level of the pisiform bone in those with CTS. Moreover, we demonstrated a significant correlation between u-CSA and median motor conduction parameters. Our findings highlighted the potential importance of neuromuscular ultrasonography in the detection of distal ulnar neuropathy in those patients, even before evident functional changes could be detected by electrodiagnostic evaluation. Finally, more precise sonographic parameters for measuring distal ulnar neuropathy are needed due to the lack of standardized cut-off values for normal u-CSA at this site and the scarcity of available studies on distal ulnar neuropathy due to the relative rarity of this condition.

Abbreviations

AAEM	American Association of Electrodiagnostic Medicine
ADM	Abductor digiti-minimi
APB	Abductor pollicis brevis
CMAP	Compound muscle action potential
CSA	Cross-sectional area
CT	Carpal tunnel
CTS	Carpal tunnel syndrome
DI	Dorsal interosseus
DML	Distal motor latency
GC	Guyon's canal
GCS	Guyon's canal syndrome
IQR	Interquartile range
m	Median nerve
MCV	Motor conduction velocity
SD	Standard deviation
SR	Swelling ratio
OPA	Onset to peak amplitude
PSL	Peak sensory latency
SCV	Sensory conduction velocity
SNAP	Sensory nerve action potential
TCL	Transverse carpal ligament

Acknowledgements

Not applicable.

Authors' contributions

All authors shared in writing and reviewing the manuscript. All authors read and approved the final manuscript.

Funding

No funding.

Availability of data and materials

The data sets used are available from the corresponding author on reasonable request.

Declarations

Ethics approval and consent to participate

IRB NO: 00012098, ethical board Alexandria University.
A written consent was signed by all the participants.

Consent for publication

Not applicable.

Competing interests

The authors declare that they have no competing interests.

Received: 1 November 2023 Accepted: 20 December 2023
Published online: 11 January 2024

References

1. Doughty CT, Bowley MP (2019) Entrapment neuropathies of the upper extremity. Med Clin North Am 103(2):357–370. https://doi.org/10.1016/j.mcna.2018.10.012. PMID: 30704687
2. Schmid AB, Fundaun J, Tampin B. Entrapment neuropathies: a contemporary approach to pathophysiology, clinical assessment, and management. Pain Rep. 2020;5(4):e829. https://doi.org/10.1097/PR9.0000000000000829. PMID: 32766466; PMCID: PMC7382548.
3. Wipperman J, Goerl K (2016) Carpal tunnel syndrome: diagnosis and management. Am Fam Physician 94(12):993–999. PMID: 28075090
4. Caliandro P, La Torre G, Aprile I, Pazzaglia C, Commodari I, Tonali P et al (2006) Distribution of paresthesias in carpal tunnel syndrome reflects the degree of nerve damage at the wrist. Clin Neurophysiol 117:228–231
5. Zanette G, Cacciatori C, Tamburin S (2010) Central sensitization in carpal tunnel syndrome with extraterritorial spread of sensory symptoms. Pain 148:227–236
6. Tecchio F, Padua L, Aprile I, Rossini PM (2002) Carpal tunnel syndrome modifies sensory hand cortical somatotopy: a MEG study. Hum Brain Mapp 17:28–36
7. Ginanneschi F, Mondelli M, Cioncoloni D, Rossi A (2018) Impact of carpal tunnel syndrome on ulnar nerve at wrist: Systematic review. J Electromyogr Kinesiol 40:32–38. https://doi.org/10.1016/j.jelekin.2018.03.004. Epub 2018 Mar 20 PMID: 29587171
8. Kang S, Yang SN, Yoon JS, Kang HJ, Won SJ (2016) Effect of carpal tunnel syndrome on the ulnar nerve at the wrist: sonographic and electrophysiologic studies. J Ultrasound Med 35(1):37–42. https://doi.org/10.7863/ultra.15.02064. Epub 2015 Nov 20 PMID: 26589645
9. American Association of Electrodiagnostic Medicine, American Academy of Neurology, and American Academy of Physical Medicine and Rehabilitation. Practice parameter for electrodiagnostic studies in carpal tunnel syndrome: summary statement. Muscle Nerve. 2002;25(6):918–22. https://doi.org/10.1002/mus.10185. PMID: 12115985.
10. Padua L, LoMonaco M, Gregori B, Valente EM, Padua R, Tonali P (1997) Neurophysiological classification and sensitivity in 500 carpal tunnel syndrome hands. Acta Neurol Scand 96:211–217
11. Katz JN, Stirrat CR (1990) A self-administered hand diagram for the diagnosis of carpal tunnel syndrome. J Hand Surg Am 15:360–363
12. Jablecki CK, Andary MT, Floeter MK, Miller RG, Quartly CA, Vennix MJ et al (2002) Practice parameter: electrodiagnostic studies in carpal tunnel syndrome: report of the American Association of Electrodiagnostic Medicine, American Academy of Neurology, and the American Academy of Physical Medicine and Rehabilitation. Neurology 58:1589–1592
13. Buchberger WW, Schon G, Strasser K, Jungwirth W (1991) Highresolution ultrasonography of the carpal tunnel. J Ultrasound Med 10:531–537
14. Karvelas KR, Walker FO (2019) Clinical and ultrasonographic features of distal ulnar neuropathy: a review. Front Neurol 24(10):632. https://doi.org/10.3389/fneur.2019.00632. PMID:31293494;PMCID:PMC6601364
15. Niu J, Li Y, Zhang L, Ding Q, Cui L, Liu M (2020) Cross-sectional area reference values for sonography of nerves in the upper extremities. Muscle Nerve 61(3):338–346. https://doi.org/10.1002/mus.26781. Epub 2019 Dec 30 PMID: 31837161
16. Kanagasabai K (2022) Ultrasound of median nerve in the diagnosis of carpal tunnel syndrome-correlation with electrophysiological studies. Indian J Radiol Imaging 32(1):16–29. https://doi.org/10.1055/s-0041-1741088. PMID: 35722647;PMCID:PMC9203152
17. Chang YW, Hsieh TC, Tzeng IS, Chiu V, Huang PJ, Horng YS (2019) Ratio and difference of the cross-sectional area of median nerve to ulnar nerve in diagnosing carpal tunnel syndrome: a case control study. BMC Med Imaging 19(1):52. https://doi.org/10.1186/s12880-019-0351-3. PMID:31272405;PMCID:PMC6610846
18. Xu C, Zhou Y, He Z, Liu W, Zou M, Sun Y, Qiu J, Ren Y, Mao G, Wang Y, Xi Q, Chen Y, Zhang B (2022) Difference and ratio of the cross-sectional area of median nerve at the carpal tunnel and the pronator quadratus muscle in diagnosing carpal tunnel syndrome: a cross-sectional study. Ann Transl Med 10(6):340. https://doi.org/10.21037/atm-22-1128. PMID:35433935;PMCID:PMC9011265
19. Yemisci OU, Yalbuzdag SA, Cosar SN, Oztop P, Karatas M (2011) Ulnar nerve conduction abnormalities in carpal tunnel syndrome. Muscle Nerve 44(3):352–357
20. Mansiz-Kaplan B, Akdeniz-Leblecicier M, Yagci I (2018) Are extramedian symptoms associated with peripheral causes in patient with carpal tunnel syndrome? Electrodiagnostic and ultrasonographic study. J Electromyogr Kinesiol 38:203–207. https://doi.org/10.1016/j.jelekin.2017.08.003. Epub 2017 Aug 10 PMID: 28818412
21. Sedal L, Mc Leod JC, Walsh JC (1973) Ulnar nerve lesions associated with carpal tunnel syndrome. J Neurol Neurosurg Psychiatry 36(1):118–123
22. Ginanneschi F, Milani P, Mondelli M, Dominici F, Biasella A, Rossi A (2008) Ulnar sensory nerve impairment at the wrist in carpal tunnel syndrome. Muscle Nerve 37(2):183–189
23. Azmy RM, Labib AA, Elkholy SH (2013) Axonal degeneration of the ulnar nerve secondary to carpal tunnel syndrome: fact or fiction? Neural Regen Res 8(15):1418–1422
24. Zhang J, Liu N, Wang YW, Zhang ZC, Zheng LN, Zhu J (2015) Evaluation of the function status of the ulnar nerve in carpal tunnel syndrome. Genet Mol Res 14(2):3680–3686
25. Sakly G, Affes Z, Dhia SB, Trabelsi A, Cheikh RB, Gammoudi N, Dogui M (2016) The impact of carpal tunnel syndrome on ulnar nerve: an electro-clinical study. J Neurol Neurosci 7–5:153
26. Selek Ö, Alemdar M (2017) Are the sensory fibers of the ulnar nerve affected in carpal tunnel syndrome? J Clin Neurophysiol 34(6):502–507
27. El-Hady AO, El Molla SSA, Ibrahim RA (2020) Evaluation of axonal loss in ulnar sensory nerve fibers recorded from ring and little fingers secondary to idiopathic carpal tunnel syndrome in Egyptian patients. Egypt Rheumatol Rehabil 47:9. https://doi.org/10.1186/s43166-020-00004-7
28. Kose Ozlece H, Huseyinoglu N, Gok M, Ilik F (2016) Ultrasonographic and electrophysiological evaluation of the ulnar nerve in patients diagnosed with carpal tunnel syndrome. J Clin Neurophysiol 33(5):464–468
29. Moghtaderi A, Ghafarpoor M (2009) The dilemma of ulnar nerve entrapment at wrist in carpal tunnel syndrome. Clin Neurol Neurosurg 111(2):151–155
30. Imai T, Matsumoto H, Minami R (1990) Asymptomatic ulnar neuropathy in carpal tunnel syndrome. Arch Phys Med Rehab 71(12):992–994
31. Vahdatpour B, Raissi GR, Hollisaz MT (2007) Study of the ulnar nerve compromise at the wrist of patients with carpal tunnel syndrome. Electromyogr Clin Neurophysiol 47(3):183–186
32. Cassvan A, Rosenberg A, Rivera LF (1986) Ulnar nerve involvement in carpal tunnel syndrome. Arch Phys Med Rehabil 67:290–292
33. Gozke E, Dortcan N, Kocer A, Cetinkaya M, Akyuz G, Us O (2003) Ulnar nerve entrapment at wrist associated with carpal tunnel syndrome. Neurophysiol Clin 33(5):219–222
34. Ginanneschi F, Milani P, Rossi A (2008) Anomalies of ulnar nerve conduction in different carpal tunnel syndrome stages. Muscle Nerve 38(3):1155–1160
35. Kiylioglu N, Akyildiz UO, Ozkul A, Akyol A (2011) Carpal tunnel syndrome and ulnar neuropathy at the wrist: comorbid disease or not? J Clin Neurophysiol 28(5):520–523
36. Mortier G, Deckers K, Dijs H, Vander Auwera JC (1988) Comparison of the distal motor latency of the ulnar nerve in carpal tunnel syndrome with a control group. Electromyogr Clin Neurophysiol 28(2–3):75–77
37. Al-Hashel JY, Rashad HM, Nouh MR, Amro HA, Khuraibet AJ, Shamov T, Tzvetanov P, Rousseff RT (2015) Sonography in carpal tunnel syndrome with normal nerve conduction studies. Muscle Nerve 51(4):592–597. https://doi.org/10.1002/mus.24425. Epub 2015 Feb 24 PMID: 25131376

38. Aktürk S, Büyükavcı R, Ersoy Y (2020) Median nerve ultrasound in carpal tunnel syndrome with normal electrodiagnostic tests. Acta Neurol Belg 120(1):43–47. https://doi.org/10.1007/s13760-018-0963-3. Epub 2018 Jun 11 PMID: 29949031
39. Azami A, Maleki N, Anari H, IranparvarAlamdari M, Kalantarhormozi M, Tavosi Z (2014) The diagnostic value of ultrasound compared with nerve conduction velocity in carpal tunnel syndrome. Int J Rheum Dis 17(6):612–620. https://doi.org/10.1111/1756-185X.12310. Epub 2014 Feb 20 PMID: 24618125
40. Csillik A, Bereczki D, Bora L, Arányi Z (2016) The significance of ultrasonographic carpal tunnel outlet measurements in the diagnosis of carpal tunnel syndrome. Clin Neurophysiol 127(12):3516–3523. https://doi.org/10.1016/j.clinph.2016.09.015. Epub 2016 Oct 3 PMID: 27815975
41. Bathala L, Kumar P, Kumar K, Visser LH (2013) Ultrasonographic cross-sectional area normal values of the ulnar nerve along its course in the arm with electrophysiological correlations in 100 Asian subjects. Muscle Nerve 47:673–676
42. Cartwright MS, Shin HW, Passmore LV, Walker FO (2007) Ultrasonographic findings of the normal ulnar nerve in adults. Arch Phys Med Rehabil 88:394–396
43. Ginanneschi F, Filippou G, Reale F, Scarselli C, Galeazzi M, Rossi A (2010) Ultrasonographic and functional changes of the ulnar nerve at Guyon's canal after carpal tunnel release. Clin Neurophysiol 121(2):208–213
44. Eom YI, Choi MH, Kim YK, Joo IS (2015) Sonographic findings in the ulnar nerve according to the electrophysiologic stage of carpal tunnel syndrome. J Ultrasound Med 34(6):1027–1034
45 Shriki J (2014) Ultrasound physics. Crit Care Clin. 30(1):1–24, v. https://doi.org/10.1016/j.ccc.2013.08.004. PMID: 24295839
46. Okutsu I, Hamanaka I, Yoshida A (2009) Pre- and postoperative Guyon's canal pressure change in endoscopic carpal tunnel release: correlation with transient postoperative Guyon's canal syndrome. J Hand Surg Eur 34(2):208–211. https://doi.org/10.1177/1753193408100122. Epub 2009 Mar 12 PMID: 19282410
47. Ablove RH, Moy OJ, Peimer CA, Wheeler DR, Diao E (1996) Pressure changes in Guyon's canal after carpal tunnel release. J Hand Surg Br 21(5):664–665. https://doi.org/10.1016/s0266-7681(96)80155-0. PMID: 9230958
48. Ablove RH, Peimer CA, Diao E, Oliverio R, Kuhn JP (1994) Morphologic changes following endoscopic and two-portal subcutaneous carpal tunnel release. J Hand Surg Am 19(5):821–826. https://doi.org/10.1016/0363-5023(94)90194-5. PMID: 7806811
49. Richman JA, Gelberman RH, Rydevik BL, Hajek PC, Braun RM, Gylys-Morin VM, Berthoty D (1989) Carpal tunnel syndrome: morphologic changes after release of the transverse carpal ligament. J Hand Surg Am 14(5):852–857. https://doi.org/10.1016/s0363-5023(89)80089-9. PMID: 2794405

Publisher's Note